

Original article

Ultrasound-guided platelet-rich plasma injections for the treatment of osteoarthritis of the hip

Mikel Sánchez¹, Jorge Guadilla¹, Nicolás Fiz¹ and Isabel Andia²

Abstract

Objective. To assess the safety and symptomatic changes of IA injections of platelet-rich plasma (PRP) in patients with OA of the hip.

Methods. Forty patients affected by monolateral severe hip OA were included in the study. Each joint received three IA injections of PRP, which were administered once a week. The primary end point was meaningful pain relief, which was described as a reduction in pain intensity of at least 30% from baseline levels as evaluated by the WOMAC subscale at 6-months post-treatment. The visual analogue scale (VAS) and Harris hip score subscale for pain were used to verify the results. Secondary end points included changes in the level of disability of at least 30% and the percentage of positive responders, i.e. the number of patients that achieved a >30% reduction in pain and disability.

Results. Statistically significant reductions in VAS, WOMAC and Harris hip subscores for pain and function were reported at 7 weeks and 6 months ($P < 0.05$). Twenty-three (57.5%) patients reported a clinically relevant reduction of pain (45%, range 30–71%) as assessed by the WOMAC subscale. Sixteen (40%) of these patients were classified as excellent responders who showed an early pain reduction at 6–7 weeks, which was sustained at 6 months, and a parallel reduction of disability. Side effects were negligible and were limited to a sensation of heaviness in the injection site.

Conclusions. This preliminary non-controlled prospective study supported the safety, tolerability and efficacy of PRP injections for pain relief and improved function in a limited number of patients with OA of the hip.

Key words: platelet-rich plasma, hip, osteoarthritis, ultrasound

Introduction

OA is a syndrome of joint pain and dysfunction that is caused by joint degeneration. OA affects more people than any other joint disease [1] and has widespread economic and social consequences. The hip is a frequent site for OA, and the prevalence ranges from 7 to 25% in Caucasians aged >55 years [2]. The problem is likely intensified by current demographic trends, including the pandemic of obesity and the higher recreational activity levels of our elderly population [3]. Indeed, there is an urgent need for disease-modifying treatments to stop or

at least slow the development and progression of OA. For this treatment to be possible, the aetiopathogenic mechanisms and OA progression that target specific tissues require further elucidation. Meanwhile, the administration of platelet-rich plasma (PRP) has gained attention from the scientific and medical communities because of its ability to release a large pool of chemokines, cytokines and growth factors within the joint capsule [4], which are involved in cell signalling and in the stimulation of intrinsic repair mechanisms. IA injections of PRP are currently hypothesized to largely control the activities of different cell types that target multiple biological processes, such as apoptosis, extracellular matrix synthesis, the modulation of angiogenesis and inflammation [5].

PRP therapy was first applied after IA knee injury [6] and, later, for knee OA [7], because PRP may substitute the chondrodestructive environment with high levels of anabolic and chondroprotective cytokines. PRP-released cytokines target the synovium and induce changes in the SF [8, 9]. In the IA milieu, cytokines and growth factors

¹Unidad de Cirugía Artroscópica, UCA 'Mikel Sánchez', Clínica USP-La Esperanza, Vitoria-Gasteiz, Spain and ²Departamento de Investigación, Osakidetza, Basque Health Service, Zamudio, Vizcaya. Submitted 27 April 2011; revised version accepted 19 July 2011.

Correspondence to: Isabel Andia, Departamento de Investigación, Osakidetza, Basque Health Service, B° Arteaga 107, 48170 Zamudio, Vizcaya. E-mail: iandia2010@hotmail.com

may diffuse from plasma or from SF towards chondrocytes or subchondral bone, where they bind to cell surface receptors and stimulate cellular functions. In knee OA, Sánchez *et al.* [7] reported decreased pain and enhanced function, which was assessed using the WOMAC scale, after an IA injection of activated, pure PRP compared with an IA injection of HA in a retrospective cohort study (Level III). More recently, in a case series study (Level IV) that involved 115 knees of young patients with low degrees of articular degeneration, Kon and colleagues [10, 11] reported reduced pain and improved function after leucocyte-PRP treatment. Sampson *et al.* [12] also reported a decrease in symptoms after three IA injections of PRP in the OA knee.

Based on these results, the application of PRP within the hip joint is of great interest as a potential novel treatment. Here, we report the clinical effects of US-guided PRP injections on the management of hip OA in a case series study. This was a pragmatic and preliminary study that assessed the safety and potential value of PRP treatment, which is an essential task for future clinical trials.

Methods

A prospective case series study was performed to test the safety and effectiveness of IA treatments with PRP. The Institutional Review Board of United Surgical Partners Hospitals approved the study, and all patients signed a detailed informed consent form, according to the Declaration of Helsinki. Patients fulfilled the ACR diagnostic criteria for hip OA [13]. Two experienced orthopaedic surgeons independently examined digitized radiographs of the involved hips and determined the degree of OA according to the classification scheme developed by Tönnis [14]. Pain at baseline was of at least mild intensity, >20/100 on a 100-mm visual analogue scale (VAS).

Exclusion criteria were young patients aged <30 years, protrusio acetabuli, concentric femoral head migration, extensive surgery of the reference joint (i.e. osteotomies around the hip, open or arthroscopic osteochondroplasty for femoroacetabular impingement), excessive deformity (i.e. acetabular or femoral head dysplasia, collapse deformity and deformed femoral head sequelae of Perthes), patients with bilateral OA of the hips, concomitant rheumatic illness, poor general health that interfered with assessments, IA depot CS or HA injection and tidal lavage in the preceding 3 months. Symptomatic slow-acting drugs were withdrawn before PRP treatment. Concurrent medications, such as paracetamol or NSAIDs, were permitted but discontinued 48 h before the VAS, WOMAC and Harris assessments.

PRP treatment

PRP preparation

A total of 40 ml of peripheral venous blood was withdrawn into 9 ml tubes containing 3.8% (weight/vol) sodium citrate. PRP was prepared by centrifugation at 580g for 8 min at room temperature (PRGF, Vitoria, Spain).

The 2 c.c. plasma fraction, which was located just above the sedimented red blood cells, and the buffy coat were collected in a sterile tube under vertical air flow conditions. Calcium chloride (10%) was added at a final concentration of 22.8 mM shortly before the IA injection; 8 c.c. of PRPs were injected.

US-guided PRP injection

A 5–10 MHz multi-frequency linear probe aligned with the long axis of the femoral head was used. An IA injection was performed by the insertion of a 20- to 22-gauge spinal needle (90–120 mm) under sterile conditions. The PRP was injected at the base of the femoral neck, and a complete evacuation of IA fluid, if present, was performed. The anterosuperior, parasagittal approach allows for an injection over the femoral head, and the PRP is evenly distributed on the cartilage of both the femoral head and the acetabulum. Proper needle position was confirmed by direct visualization of the liquid PRP that was injected (Fig. 1).

Treatment schedule

Three injections were performed, and the interval between injections ranged from 1 to 2 weeks. These criteria were largely arbitrary based on our clinical experience with knee OA [7].

Outcome evaluation

Patients filled out the validated Spanish version of the WOMAC questionnaire [15]; the Harris hip score [16] was self-administered at baseline and again after 6–7 weeks and at 6 months. These indexes consist of questions regarding pain and the activities of daily living over the previous 2 days.

Primary outcome

The primary efficacy criterion was a reduction in pain intensity as measured by the WOMAC subscale, which evaluates five items for a total of 20 points (Likert format, 0–4), and the 100-mm VAS for pain intensity; lower scores are associated with less pain. The domain of pain in the traditional Harris hip score, in which higher scores are associated with less pain (out of 44 points), was used to further corroborate pain relief.

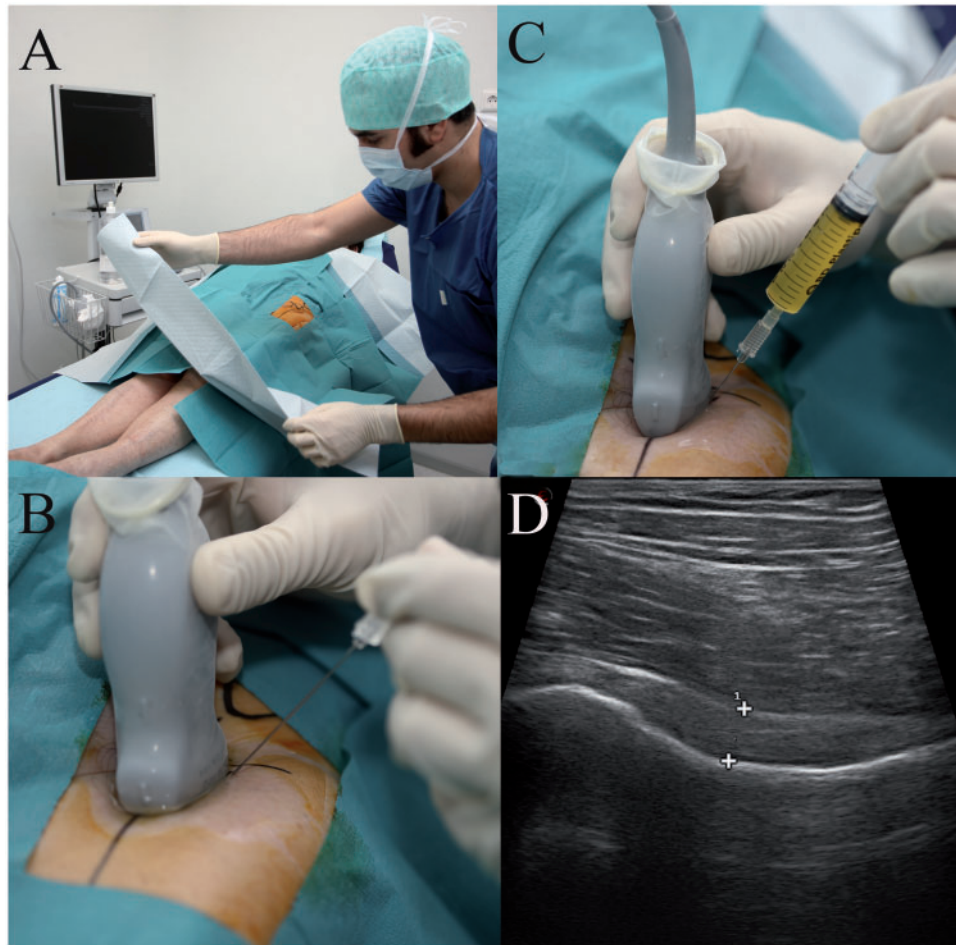
Secondary outcome

Secondary outcome measures included the proportion of responders; patients were identified as responders if they achieved a reduction in baseline VAS and WOMAC pain subscore of >30%. Secondary efficacy variables also included changes in physical function using the WOMAC subscale (17 items for a total of 68 points). The Harris hip score (7 items for a total of 47 points) was used to verify the results.

Statistical analysis

Data are expressed as the mean (s.e.), unless otherwise indicated. All raw data were screened and evaluated for parametric and non-parametric analyses of the normal distribution using visual inspection of graphics and

Fig. 1 US-guided PRP injection for hip OA. **(A)** The procedure was performed in sterile conditions in an outpatient setting. **(B)** The multi-frequency linear probe was aligned with the long axis of the femoral head and a 20- to 22-gauge spinal needle (90–120 mm) was inserted antero-inferiorly. **(C)** PRP (8 ml) was injected at the base of the femoral neck. **(D)** The accuracy of the injection was confirmed by direct visualization of the liquid PRP within the joint.



statistical testing. Wilcoxon's matched pair test was used to examine pain and dysfunction differences between baseline and 6–7 weeks or 6 months. Correlations between BMI and outcome were explored using Spearman's rho. Clinically relevant percentage changes (>30%) in pain and function were used to estimate the number of responders. The inter-observer agreement of radiographic classification was calculated with the κ -value. Radiographic severity and the presence or absence of clinical response were evaluated using Pearson's chi-square test. A $P \leq 0.05$ was considered statistically significant. Statistical analyses were performed using SPSS version 15.0 (SPSS, Chicago, IL, USA).

Results

Patient's description

From March 2008 to January 2010, 40 Caucasian patients who met the inclusion criteria were included in the study

and received three PRP injections. Patient baseline data are summarized in Table 1. According to conventional BMI criteria (e.g. overweight is a BMI of 25–29.9 kg/m² and obesity is a BMI ≥ 30 kg/m²), 9 patients were obese, 17 were overweight and 14 had normal weight. High levels of radiographic damage (Tönnis 3) were observed in 70% of the hips. The inter-observer agreement was good ($\kappa = 0.81$). The average pain VAS score at baseline was 52.0 mm (s.d. 14.8 mm) on a 100-mm scale. No fluid was aspirated from any of the hip joints. Three patients had OA in the knee or ankle and had been previously treated with PRP. All patients completed the 6-month follow-up. A summary of the VAS, Harris and WOMAC raw scores over the study period is shown in Figs 2 and 3.

Pain

There was a significant reduction in the WOMAC pain scores over the 6- to 7-week ($W = 438$, $P = 0.00047$) and 6-month periods ($W = 516$, $P = 0.00607$). The results were

TABLE 1 Demographic data and characteristics of hip OA in 40 study patients

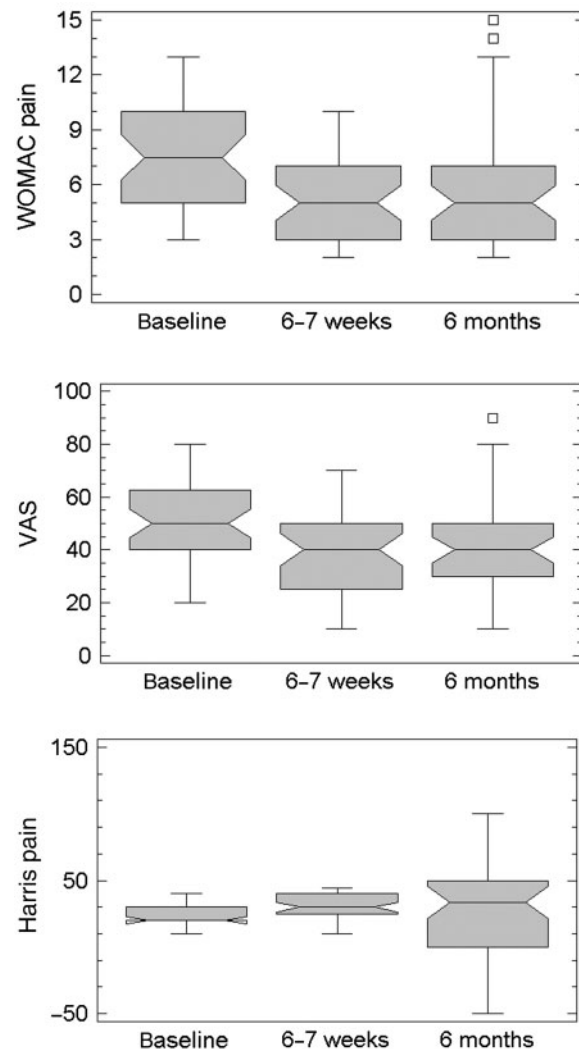
Sex, <i>n</i> (%)	
Male	27 (69.2)
Female	12 (26.7)
Age, years	
Mean (s.d.)	56 (11.9)
Range	33–84
BMI, kg/m ²	
Mean (s.d.)	26.64 (3.78)
Range	17.99–33.22
Affected hip, <i>n</i> (%)	
Right	14 (35)
Left	26 (65)
Radiographic grade, ^a <i>n</i> (%)	
Tönnis 2	12 (30)
Tönnis 3	28 (70)
VAS pain score at baseline in mm, <i>n</i> (%)	
<50	10 (22.2)
50–80	28 (70)
>80	2 (5)
NSAID therapy, <i>n</i> (%)	
Yes	29 (72.5)
No	7 (17.5)
Sy-SADOA (before PRP), <i>n</i> (%)	
Yes	10 (25)
No	30 (75)

^aRadiographic severity was assessed using the Tönnis scale: Grade 2 indicates small cysts in the femoral head or acetabulum, an increased narrowing of the joint space and a moderate loss of sphericity of the femoral head; Grade 3 is characterized by large cysts around the hip, a severe narrowing of the joint space and a severe deformity of the femoral head. Sy-SADOA: symptomatic slow-acting drug for OA.

confirmed by reductions in the VAS scale (6–7 weeks: $W=446.5$, $P=0.00062$; 6 months: $W=647$, $P=0.00606$) and in the Harris pain subscale (6–7 weeks: $W=1148$, $P=0.0004$; 6 months: $W=1106$, $P=0.0021$). There were no significant changes in pain scores between the 6- to 7-week and 6-month time points (Fig. 2). Good correlations (Spearman's rho) were found between the WOMAC and VAS scores ($r=0.7304$, $P=0.0000$) and between the WOMAC and Harris scores ($r=-0.6832$, $r=0.0000$). The results of the univariate analysis revealed that age, BMI, gender and radiographic severity were not significantly related to pain relief.

Function

The current study evaluated the function using the WOMAC domain for disability. Disability was significantly reduced in the self-reported WOMAC subscale at the 6- to 7-week ($W=545$, $P=0.0142$) and 6-month ($W=575$, $P=0.0306$) time points. Function was significantly ameliorated when the Harris hip scores at 6–7 weeks ($W=1160.5$, $P=0.0005$) and 6 months ($W=1106$, $P=0.0031$) were used as an index (Fig. 3).

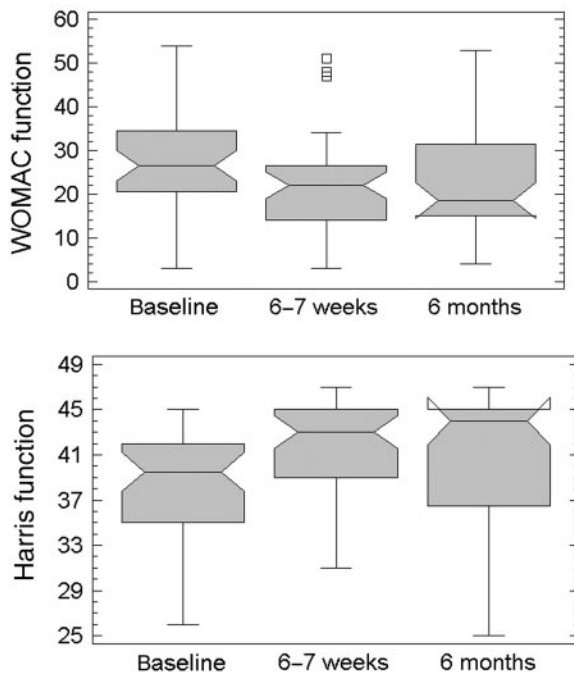
Fig. 2 Primary outcome data. Box plots for WOMAC, VAS and Harris hip pain subscores at baseline, 6–7 weeks and 6 months. Summary of all individual data expressed as box plots showing the median and 25th and 75th percentiles.

Positive responders at 6 months post-treatment

Twenty-three (57.5%) patients reported a clinically relevant relief of pain (45% reduction, range 30–71%), as assessed by the WOMAC subscale. Sixteen (40%) of these patients were classified as excellent responders, showing early pain reduction at 6–7 weeks that was sustained at 6 months with a parallel reduction of disability (> 30%).

Treatment was not effective in 11 (27.5%) patients; 10 of these patients (Tönnis 3) presented high levels of radiographic damage. Six other patients exhibited small changes that were not clinically relevant. Six patients underwent surgery; total hip replacement was performed in four patients, and two other patients had partial hip resurfacing.

Fig. 3 Box plots for WOMAC and Harris hip function subscores at baseline, 6–7 weeks and 6 months. Summary of all individual data expressed as box plots showing the median and 25th and 75th percentiles.



Safety data

One patient reported a mild rash after the second PRP injection, which was not necessarily related to treatment, and the rash disappeared spontaneously. Most patients reported a transient sensation of heaviness in the injected joint. No septic complications were reported.

Discussion

Therapy for OA of the hip has two major objectives: to relieve pain and to preserve function. Constant pain becomes a main clinical feature of hip OA later in the disease and is the focus of novel treatments [17]. Three IA injections of PRP, which were administered under US control at weekly intervals, resulted in clinically significant reductions in pain and function in a limited number of patients with severe hip OA up to 6 months post-treatment. PRP exerts multiple biological actions, including modulatory effects on inflammation and angiogenesis, which may translate clinically to pain relief, a result that was found in this study. Clinically meaningful musculoskeletal pain relief is often described as a reduction in pain intensity of ~30% from the baseline level [18], and in this study, reductions in pain intensity ranged from 30 to 71% in 60% of patients 6 months post-treatment, supporting the role of PRP as a potential treatment option. Systemic OA treatments commonly focus on inflammatory pain, and the most recent approaches focus

on neuropathic pain. In a recent study, Lane *et al.* [19] reported pain reductions that ranged from 45 to 62% in knee OA after two i.v. injections of tanezumab, which is an mAb that blocks nerve growth factor. Alternatively, other therapeutic approaches, such as non-selective NSAIDs that inhibit cyclooxygenase (COX)-1- and COX-2-mediated production of prostaglandins and the newest COX-2 inhibitors are widely used to treat inflammatory pain, but they encompass a short duration of pain relief and often cause relevant systemic adverse side effects [20].

An advantageous route of therapy administration is local injection in the joint space. It is of special interest to reach a proper concentration of active signalling proteins at the joint site without systemic exposure and to avoid adverse effects and drug interactions. Indeed, point-of-care ultrasonography has extended IA approaches to make the hip more accessible, which improves injection accuracy and permits the efficient diagnosis of inflammation [21, 22]. Ultrasonography also allows the aspiration of pathological joint fluid and the deposition of PRP under visual control, which avoids damage to femoral vessels and nerves. We injected a high volume compared with other IA treatments (e.g. HA or CS treatment usually injects 3 ml) and relative to the potential hip joint volume. This injection volume was based on non-systematic observations from our previous clinical experience. Essentially, 8 ml of PRP induced pressure changes within the hip that allowed fluid and small signalling proteins to pass and diffuse into the tissue spaces of the joint capsule to reach several structures, specifically pain fibres in the synovium, ligaments near insertions, bone and labrum [21, 22]. However, other mechanisms may be responsible for pain reduction [23]. For instance, in addition to increasing interstitial fluid pressure, IA hip injections may dilute the amount of inflammatory products within the joint. PRP treatment reduced pain and significantly improved function, exceeding the effect of CS injection in chronic lateral epicondylitis [24, 25]. Moreover, PRP could be just as efficient as placebo as previously shown in Achilles tendinopathy [26, 27]. In OA, placebo treatment affected pain reduction, but it was more effective in hand or knee OA than in the hip [28]. Nevertheless, many fundamental aspects of PRP therapies have been attributed to platelet-secreted signalling proteins [4]. Therefore, the expected therapeutic effects rely on PRP molecular complexity and require an in-depth understanding of healing pathways, the molecular composition of a particular PRP and functionality in a given microenvironment [29].

Although the mechanism of PRP action remains elusive, several different biological pathways may mediate clinical effectiveness. PRP modulates angiogenesis and inflammation, targets multiple regenerative processes by reaching different cell phenotypes and dilutes and replaces pro-inflammatory cytokines with anabolic growth factors in the joint environment [29]. The variety of PRP formulations is large. We chose pure PRP with a moderate

enrichment in platelets (1.4-fold in the peripheral blood) and without leucocytes to avoid neutrophil release of pro-inflammatory cytokines and elastases, which degrade growth factors [30]. Some of the signalling proteins in this particular PRP have been assessed previously by our laboratory [31]. Among the growth factors and cytokines that are relevant to OA, PRP delivers platelet-derived growth factor-AB, TGF- β 1, VEGF-A, hepatocyte growth factor and insulin-like growth factor. PRP also contains tissue inhibitors of metalloproteases (TIMP-1, TIMP-2, TIMP-3 and TIMP-4) and β -thromboglobulin, which neutralizes the action of destructive metalloproteases [32]. The molecular complexity of PRP is crucial, suggesting that it can interfere with macrophage inflammatory activation or chondrocyte apoptosis and mediate other cellular mechanisms, such as cell migration, proliferation or the anabolic actions of chondrocytes.

Despite the obvious differences in molecular complexity, PRP and HA have analogies. For example, both of these therapies rely on complex mechanisms of action beyond lubrication, and the symptomatic benefit generally occurs a few weeks after treatment. Moreover, the benefit is not equally distributed among patients; some patients are non-responders, as shown by the present literature [32, 33]. Both PRP and HA treatments could be improved by a *priori* identification of patients who are suitable for these treatments. Presumably, in this context, the use of molecular orthopaedics and clinical markers would advance the field. Indeed, the choice of the type of treatment for each patient that was individually based on predictors of response provides an obvious advantage for successful treatments [22].

Although the limitations of this pragmatic clinical study need to be acknowledged, it informed an area that had little previous research. The results of this study must be considered in light of its major limitations: the absence of a control group and the limited sample size. The present pragmatic study measured the effect of treatment under the conditions of our routine clinical practice in a private clinical setting. This group of patients reflected our real patient population with their comorbidities; therefore, we did not exclude patients even if they were waiting for surgery. Despite these weaknesses, our study provided preliminary insight into the therapeutic potential and limitations of PRP injections for hip OA. The effectiveness of this research should stimulate future randomized clinical trials. Although these preliminary results were encouraging, the percentage of non-responder patients underscores the urgent need for the development of criteria that identify candidate patients for PRP treatment.

Rheumatology key messages

- PRP injections improved pain and function in a limited number of patients with severe hip OA.
- Several biological pathways, including modulation of inflammation and angiogenesis, may mediate the effectiveness of PRP therapy.

Acknowledgements

The authors thank Elena Nogales for her kind assistance with data collection.

Disclosure statement: The authors have declared no conflicts of interest.

References

- 1 Buckwalter JA, Martin JA. Osteoarthritis. *Adv Drug Deliv Rev* 2006;58:150–67.
- 2 Juhakoski R, Heliövaara M, Impivaara O *et al.* Risk factors for the development of hip osteoarthritis: a population-based prospective study. *Rheumatology* 2009;48:83–7.
- 3 Sperazza LJ, Banerjee P. Baby boomers and seniors: understanding their leisure values enhances programs. *Activ Adapt Aging* 2010;34:196–215.
- 4 Nurden AT. Platelets, inflammation and tissue regeneration. *Thromb Hemost* 2011, Advance Access published 11 April 2011, doi:10.1160/TH10-11-0720.
- 5 Anitua E, Sánchez M, Nurden AT, Nurden P, Orive G, Andia I. New insights into and novel applications for platelet-rich fibrin therapies. *Trends Biotechnol* 2006;24:227–34.
- 6 Sánchez M, Azofra J, Anitua E *et al.* Plasma rich in growth factors to treat an articular cartilage avulsion: a case report. *Med Sci Sport Exer* 2003;35:1648–53.
- 7 Sánchez M, Anitua E, Azofra J, Aguirre JJ, Andia I. Intra-articular injection of an autologous preparation rich in growth factors for the treatment of knee OA: a retrospective cohort study. *Clin Exp Rheumatol* 2008;26:910–3.
- 8 Anitua E, Sánchez M, Nurden AT *et al.* Platelet-released growth factors enhance the secretion of hyaluronic acid and induce hepatocyte growth factor production by synovial fibroblasts from arthritic patients. *Rheumatology* 2007;46:1769–72.
- 9 Anitua E, Sánchez M, Zaldueño MM *et al.* Fibroblastic response to treatment with different preparations rich in growth factors. *Cell Prolif* 2009;42:162–70.
- 10 Kon E, Buda R, Filardo G *et al.* Platelet-rich plasma: intra-articular knee injections produced favorable results on degenerative cartilage lesions. *Knee Surg Sports Traumatol Arthrosc* 2010;18:472–9.
- 11 Filardo G, Kon E, Buda R *et al.* Platelet-rich plasma intra-articular knee injections for the treatment of degenerative cartilage lesions and osteoarthritis. *Knee Surg Sports Traumatol Arthrosc* 2011;19:528–35.
- 12 Sampson S, Reed M, Silvers H, Meng M, Mandelbaum B. Injections of platelet-rich plasma in patients with primary and secondary knee osteoarthritis. *Am J Phys Rehabil* 2010;89:961–9.
- 13 ACR Subcommittee on Classification Criteria of Osteoarthritis. Altman RD Chairman: the American College of Rheumatology criteria for classification and reporting of osteoarthritis of the hip. *Arthritis Rheum* 1991;34:505–14.
- 14 Tönnis D. Clinical and radiographic schemes for evaluating therapeutic results. In: Tönnis D, Legal H, Graf R, eds.

- Congenital dysplasia and dislocation of the hip in children and adults. Berlin, Germany: Springer, 1987:165-71.
- 15 Escobar A, Quintana JM, Bilbao A, Azcarate J, Guenaga JI. Validation of the Spanish version of the WOMAC questionnaire for patients with hip or knee osteoarthritis. *Clin Rheumatol* 2002;21:466-7.
- 16 Harris WH. Traumatic arthritis of the hip after dislocation and acetabular fractures: treatment by mold arthroplasty. An end-result study using a new method of result evaluation. *J Bone Surg Am* 1969;51:737-55.
- 17 Hawker GA. Experiencing painful osteoarthritis: what have we learned from listening? *Curr Opin Rheumatol* 2009;21:507-12.
- 18 Salaffi F, Stancati A, Silvestri CA, Ciapetti A, Grassi W. Minimal clinically important changes in chronic musculoskeletal pain intensity measured on a numerical rating scale. *Eur J Pain* 2004;8:283-91.
- 19 Lane NE, Achnitzer TJ, Birbara CA *et al.* Tanezumab for the treatment of pain from osteoarthritis of the knee. *N Engl J Med* 2010;363:1521-31.
- 20 Robinson P, Keenan A-M, Conaghan PG. Clinical effectiveness and dose-response of image-guided intra-articular corticosteroid injection for hip osteoarthritis. *Rheumatology* 2007;46:285-91.
- 21 Atchia I, Kane D, Reed MR, Isaacs JD, Birrell F. Efficacy of a single ultrasound-guided injection for the treatment of hip osteoarthritis. *Ann Rheum Disease* 2011;70:110-6.
- 22 Dye SF, Kaupel GL, Dye CC. Conscious neurosensory mapping of the internal structures of the human knee without intra-articular anaesthesia. *Am J Sports Med* 1998;26:773-7.
- 23 Felson DT. Developments in the clinical understanding of osteoarthritis. *Arthritis Res Ther* 2009;11:203-11.
- 24 Peerbooms JC, Sluimer J, Bruijn DJ, Gosens T. Positive effect of an autologous platelet concentrate in lateral epicondylitis in a double blind randomized controlled trial platelet-rich plasma versus corticosteroid injection with a 1-year follow-up. *Am J Sports Med* 2010;38:255-62.
- 25 Gosens T, Peerbooms JC, van Laar W, den Ouden BL. Ongoing positive effects of platelet-rich plasma versus corticosteroid injection in lateral epicondylitis: a double blind randomized trial with 2-year follow-up. *Am J Sports Med* 2011;39:1200-8.
- 26 De Vos RJ, Weir A, van Schie HTM *et al.* Platelet-rich plasma injection for chronic Achilles tendinopathy. *JAMA* 2010;303:144-9.
- 27 De Jonge S, De Vos RJ, Weir A *et al.* One-year follow-up of platelet-rich plasma treatment in chronic Achilles tendinopathy. *Am J Sports Med* 2011, Advance Access published 21 May 2011, doi:10.1177/0363546511404877.
- 28 Zhang W, Robertson J, Jones AC, Dieppe PA, Doherty M. The placebo effect and its determinants in osteoarthritis: meta-analysis of randomised controlled trials. *Ann Rheum Dis* 2008;67:1716-23.
- 29 Andia I, Sánchez M, Maffulli N. Tendon healing and PRP therapies. *Expert Opin Biol Ther* 2010;10:1415-26.
- 30 Borregaard N, Sorensen OE, Theilgaard-Monch K. Neutrophil granules: a library of innate immunity proteins. *Trends Immunol* 2001;28:340-5.
- 31 Anitua E, Sánchez M, de la Fuente M *et al.* Relationship between investigative biomarkers and radiographic grading in patients with knee osteoarthritis. *Int J Rheumatol* 2009, Advance Access published 6 April 2006, doi:10.1155/2009/747432.
- 32 Richette P, Ravaud P, Conrozier T *et al.* Effect of hyaluronic acid in symptomatic hip OA: a multicenter randomized, placebo controlled trial. *Arthritis Rheum* 2009;60:824-30.
- 33 Abate M, Pelotti P, De Amicis D A *et al.* Viscosupplementation with hyaluronic acid in hip osteoarthritis. *Upsal J Med Sci* 2008;113:261-77.