

Achilles Tendinopathy

Umile Giuseppe Longo, MD,* Mario Ronga, MD,† and
Nicola Maffulli, MD, MS, PhD, FRCS(Orth)‡

Abstract: Achilles tendinopathy is a common cause of disability. Despite the economic and social relevance of the problem, the causes and mechanisms of Achilles tendinopathy remain unclear. Tendon vascularity, gastrocnemius-soleus dysfunction, age, sex, body weight and height, pes cavus, and lateral ankle instability are considered common intrinsic factors. The essence of Achilles tendinopathy is a failed healing response, with haphazard proliferation of tenocytes, some evidence of degeneration in tendon cells and disruption of collagen fibers, and subsequent increase in non-collagenous matrix. Tendinopathic tendons have an increased rate of matrix remodeling, leading to a mechanically less stable tendon which is more susceptible to damage. The diagnosis of Achilles tendinopathy is mainly based on a careful history and detailed clinical examination. The latter remains the best diagnostic tool. Over the past few years, various new therapeutic options have been proposed for the management of Achilles tendinopathy. Despite the morbidity associated with Achilles tendinopathy, many of the therapeutic options described and in common use are far from scientifically based. New minimally invasive techniques of stripping of neovessels from the Kager's triangle of the tendo Achillis have been described, and seem to allow faster recovery and accelerated return to sports, rather than open surgery. A genetic component has been implicated in tendinopathies of the Achilles tendon, but these studies are still at their infancy.

Key Words: Achilles tendon, tendinopathy, sports, main body, athletes

(*Sports Med Arthrosc Rev* 2009;17:112–126)

Achilles tendinopathy is a clinical condition characterized by pain and swelling in and around the tendon, mainly arising from overuse, but often presenting in middle aged overweight patients with no history of increased physical activity.¹ Achilles tendinopathy is a common cause of disability in many athletes because of continuous prolonged intense functional demands imposed on the Achilles tendon (AT). In the past 3 decades, the incidence of Achilles tendinopathy has risen as a result of greater participation in recreational and competitive sports. A 10-fold increase in AT injuries has been reported in runners compared with age matched controls.² The lifetime incidence of Achilles tendinopathy in top-level runners has been estimated at around 7% to 9%. Achilles tendinopathy is also common among

athletes participating in racquet sports, track and field, volleyball, and soccer.^{3–7}

Achilles tendinopathy is not only restricted to athletes: up to one third of people affected are nonathletes who may lose significant numbers of working days, with a marked financial impact on society.⁸ The management of Achilles tendinopathy lacks evidence-based support, and tendinopathy sufferers are at risk for long-term morbidity with unpredictable clinical outcome.⁹

ANATOMY

The confluence of the gastrocnemius and soleus muscles forms the AT. The gastrocnemius is more superficial and originates from 2 heads above the knee. The soleus is anterior to the gastrocnemius and originates below the knee.¹⁰ The plantaris muscle, present in approximately 90% of the population, has a short muscle belly of 7 to 10 cm, arises just below the lateral head of gastrocnemius, and has a long slender tendon that runs medial to the AT.¹¹

There are 2 bursae at the calcaneal insertion of the AT. A subcutaneous bursa lies superficial to the tendon and the skin, and a retrocalcaneal bursa lies between tendon and the calcaneum.¹²

The AT derives its sensory nerve supply from the nerves of the attaching muscles and cutaneous nerves, in particular the sural nerve.^{9,13,14}

HISTOLOGY

The cells in a normal AT are well organized. Tenocytes and tenoblasts form up to 95% of the cellular element of the tendon.¹⁵ Specialized fibroblasts, the tenocytes, appear in transverse sections as stellate cells, possibly owing to the uniform centrifugal secretion of collagen. Tenoblasts have variable shapes and sizes, and are arranged in long parallel chains.¹⁵

Collagen constitutes about 90% of tendons protein, or approximately 70% of the dry weight of a tendon.¹⁴ The collagen fibers are tightly packed in parallel bundles.¹⁶ Type I collagen is the commonest; it forms 95% of tendon collagen, and is held in parallel bundles by small proteoglycan molecules.⁴ Elastin accounts for only about 2% of the dry mass of tendon¹⁴ and can undergo up to 200% strain before failure.

Aging significantly decreases tendon glycosaminoglycans and increases collagen concentration.¹⁷ Acute exercise increases type I collagen formation in peritendinous tissue.¹⁸

The essence of tendinopathy is a failed healing response, with haphazard proliferation of tenocytes, some evidence of degeneration in tendon cells and disruption of collagen fibers, and subsequent increase in noncollagenous matrix.^{1,14,19–21} Tendinopathic lesions affect both collagen matrix and tenocytes.^{20,22} The parallel orientation of collagen fibers is lost, there is a decrease in collagen fiber diameter and in the overall density of collagen. Collagen

From the *Department of Orthopaedic and Trauma Surgery, Campus Biomedico University, Rome; †Department of Orthopaedics and Traumatology, University of Insubria Ospedale di Circolo, Varese, Italy; and ‡Centre for Sports and Exercise Medicine, Queen Mary University of London, Barts and The London School of Medicine and Dentistry, Mile End Hospital, London, England.

Reprints: Nicola Maffulli, MD, MS, PhD, FRCS(Orth), Centre for Sports and Exercise Medicine, Queen Mary University of London, Barts and The London School of Medicine and Dentistry, Mile End Hospital, 275 Bancroft Road, London E1 4DG England (e-mail: n.maffulli@qmul.ac.uk).

Copyright © 2009 by Lippincott Williams & Wilkins

microtears may also occur, and may be surrounded by erythrocytes, fibrin, and fibronectin deposits. Normally, collagen fibers in tendons are tightly bundled in a parallel fashion. In tendinopathic samples, there is unequal and irregular crimping, loosening and increased waviness of collagen fibers, with an increase in type III (reparative) collagen.²²⁻²⁶

At electron microscopy, various types of degeneration have been described, namely (a) hypoxic degeneration, (b) hyaline degeneration, (c) mucoid or myxoid degeneration, (d) fibrinoid degeneration, (e) lipoid degeneration, (f) calcification, and (g) fibrocartilaginous and bony metaplasia.²⁷⁻²⁹ All can coexist, depending on the anatomic site and the nature of their causal insult. Therefore, tendinopathy can be considered the end result of a number of etiologic processes with a relatively narrow spectrum of histopathologic features.^{1,30,31}

In tendinopathic tendons, tenocytes are abnormally plentiful in some areas.³²⁻³⁴ They have rounded nuclei, and there is an ultrastructural evidence of increased production of proteoglycan and protein, which gives them a chondroid appearance. Other areas may contain fewer tenocytes than normal with small, pyknotic nuclei,²² with occasional infiltration of lymphocytes and macrophage type cells, possibly part of a healing process²² associated with proliferation of capillaries and arterioles. Degeneration of the AT is usually either “mucoid” or “lipoid”.²⁷ Collagen fibers that are thinner than normal, and large interfibrillar mucoid patches and vacuoles are seen.³⁵ There is an increase in the Alcian-blue-staining ground substance. The characteristic hierarchical structure is also lost.³⁶⁻³⁹ Vascularity is typically increased, and blood vessels are randomly oriented, sometimes perpendicular to collagen fibers.^{40,41} Inflammatory lesions⁴⁰⁻⁴³ and granulation tissue^{42,43} are infrequent, and, when found, are associated with partial ruptures. Inflammatory cells and acellular necrotic areas are exceptional, and probably not typical of the degenerative process.^{35,44-46} In contrast, mucoid degeneration, fibrosis, and vascular proliferation with an inflammatory infiltrate may be found in the paratenon.^{37,39-41,47,48} Using common staining techniques, light microscopic degeneration was not a feature of tendons from healthy, older persons. Type I collagen is the main collagen in tendons; type III collagen is present in small amounts.

We used an *in vitro* model to determine whether tenocytes from ATs that were ruptured, nonruptured, tendinopathic, and fetal show different behavior.⁴⁹ In cultures from ruptured and tendinopathic tendons, there was increased production of type III collagen. Athletic participation places excess stress on the AT, which could potentially lead to areas of microtrauma within the tendon. These areas may heal by the production of type III collagen, which is an abnormal healing response. Accumulation of such episodes of microtrauma could result in a critical point where the resistance of the tissue to tensile forces is compromised and tendon rupture occurs.

ETIOLOGY

The etiology of Achilles tendinopathy remains unclear, and many factors have been implicated. Tendon vascularity, gastrocnemius-soleus dysfunction, age, sex, body weight and height, pes cavus, and lateral ankle instability are common intrinsic factors.⁵⁰ Excessive motion of the hindfoot in the frontal plane, especially a lateral heel strike with excessive compensatory pronation, is thought to cause a “whipping

action” on the AT, and predispose it to tendinopathy. Also, forefoot varus is frequent in patients with Achilles tendinopathy. Changes in training pattern, poor technique, previous injuries, footwear, and environmental factors such as training on hard, slippery or slanting surfaces are extrinsic factors, which may predispose the athlete to Achilles tendinopathy. Excessive loading of tendons during vigorous physical training is regarded as the main pathologic stimulus for tendinopathy,⁵¹ possibly as a result of imbalance between muscle power and tendon elasticity. The AT may respond to repetitive supra-physiologic overload by either inflammation of its sheath, or degeneration of its body, or a combination of both.^{52,53}

It remains unclear whether different stresses induce different responses. Active repair of fatigue damage must occur, or tendons would weaken and eventually rupture. The repair mechanism is probably mediated by resident tenocytes, which continually monitor the extracellular matrix (ECM). Failure to adapt to recurrent excessive loads results in the release of cytokines leading to further modulation of cell activity.⁵¹ Tendon damage may even occur from stresses within physiologic limits, as frequent cumulative microtrauma may not allow enough time for repair.⁵⁴ Microtrauma can also result from nonuniform stress within tendons, producing abnormal load concentrations and frictional forces between the fibrils, with localized fiber damage.⁵¹

Free radical damage occurring on reperfusion after ischemia, hypoxia, hyperthermia, and impaired tenocyte apoptosis have been linked with tendinopathy.⁵⁵ In animal studies, local administration of cytokines and inflammatory agents such as prostaglandins has resulted in tendinopathy.⁵⁶ Fluoroquinolones have also been implicated in the pathogenesis of tendinopathy. Ciprofloxacin causes enhanced interleukin-1 β -mediated matrix metalloproteinase 3 (MMP3) release, inhibits tenocyte proliferation and reduces the collagen and matrix synthesis.

Degenerative tendinopathy is the most common histologic finding in spontaneous tendon ruptures. Tendon degeneration may lead to reduced tensile strength and a predisposition to rupture. Indeed, ruptured ATs have more advanced intratendinous changes than tendinopathic tendons.⁵⁷ In Achilles tendinopathy, changes in the expression of genes regulating cell-cell and cell-matrix interactions have been reported, with down-regulation of MMP3 mRNA.⁵⁸ Significantly higher levels of type I and type III collagen mRNAs have been reported in tendinopathic samples compared with normal samples. Imbalance in MMP activity in response to repeated injury or mechanical strain may result in tendinopathy.^{46,59-62}

Pain is the main symptom of Achilles tendinopathy, but the underlying mechanism causing pain is not fully understood. Traditionally, pain has been thought to arise through inflammation, or via collagen fiber separation or disruption.³¹ However, chronically painful ATs have no evidence of inflammation.⁴⁸ As tendinopathies are not inflammatory conditions, pain may originate from a combination of mechanical and biochemical causes.⁶³

METALLOPROTEASES IN TENDINOPATHY OF TENDO ACHILLIS

Tendon matrix constantly remodels, with higher rates of turnover at sites exposed to high levels of strain. Matrix metalloproteases (MMPS), a family of zinc and calcium

dependent endopeptidases active at a neutral pH, are involved in the remodeling of ECM through their broad proteolytic capability.⁶⁴ Degradation of collagen in tendon ECM is initiated by MMPs. Twenty-three human MMPs have been identified, with a wide range of extracellular substrates.⁶⁵ MMPs can be subdivided into 4 main groups: collagenases, which cleave native collagen types I, II, and III; gelatinases, which cleave denatured collagens and type IV collagen; stromelysins, which degrade proteoglycans, fibronectin, casein, collagen types III, IV, and V; and membrane type MMPs. The activity of MMPs is inhibited reversibly by tissue inhibitors of metalloproteinases (TIMPs) in a noncovalent fashion in a 1:1 stoichiometry. There are 4 types of TIMP: TIMP1, TIMP2, TIMP3, and TIMP4. The balance between the activities of MMPs and TIMPs regulates tendon remodeling, and an imbalance produces collagen disturbances in tendons.

MMP3 may play a major role in regulation of tendon ECM degradation and tissue remodeling. An increased expression of MMP3 may be necessary for appropriate tissue remodeling and prevention of tendinopathic changes.⁵⁸ The timing of MMP3 production is probably also critical in this process. MMP3 and TIMP1, TIMP2, TIMP3, and TIMP4 are down-regulated in tendinopathic tendons.⁶⁶ Decreased MMP3 expression may therefore lead to tendinopathic changes in tendons. The expression of MMP2 can be up-regulated in Achilles tendinopathy. Physical exercise can influence local MMP and TIMP activities in human tendo Achillis with a pronounced increase in local levels of pro-MMP9 after exercise.⁵⁸ MMP9 may well have a role in a potential inflammation reaction in human tendo Achillis induced by intensive exercise. Also, exercise causes a rapid increase in serum MMP9, a probable result of increased leukocytes in the circulation.⁵⁸

MMPs and their inhibitors are crucial to ECM remodeling, and a balance exists between them in normal tendons. Alteration of MMP and TIMP expression from basal levels leads to alteration of tendon homeostasis. Tendinopathic tendons have an increased rate of matrix remodeling, leading to a mechanically less stable tendon which is more susceptible to damage.^{9,31,46,59–62,67–69}

CLINICAL ASPECTS

Pain is the cardinal symptom of Achilles tendinopathy. However, it should be understood that, even though patients

may present acutely, it is likely that the histopathology, even in these instances, is already of a failed healing response nature, bearing witness to the long standing process which eventually causes clinically relevant symptoms. Generally, pain occurs at the beginning and end of a training session, with a period of diminished discomfort in between. As the pathologic process progresses, pain may occur during exercise, and, in severe cases, it may interfere with activities of daily living. In the acute phase, the tendon is diffusely swollen and edematous, and on palpation tenderness is usually greatest from 2 to 6 cm proximal to the tendon insertion. Sometimes, fibrin precipitated from the fibrinogen-rich fluid around the tendon can cause palpable crepitation. In chronic cases, exercise-induced pain is still the cardinal symptom, but crepitation and effusion diminish. A tender, nodular swelling is usually present in chronic cases, and is believed to signify tendinopathy.

The diagnosis of Achilles tendinopathy is mainly based on a careful history and detailed clinical examination. Diagnostic imaging may be required to verify a clinical suspicion or to exclude other musculoskeletal disorders, such as os trigonum syndrome, tenosynovitis or dislocation of the peroneal tendons, tenosynovitis of the plantar flexors, an accessory soleus muscle, tumors of the AT (xanthomas), and neuroma of the sural nerve.⁷⁰

Clinical examination is the best diagnostic tool. Both legs are exposed from above the knees and the patient was examined during standing and prone. The foot and the heel should be inspected for any malalignment, deformity, obvious asymmetry in the tendons size, localized thickening, Haglund heel and any previous scars. The AT should be palpated for tenderness, heat, thickening, nodule, and crepitation.⁶ The tendons excursion is estimated to determine any tightness. The “painful arc” sign helps to distinguish between tendon and paratenon lesions. In paratenonopathy, the area of maximum thickening and tenderness remains fixed in relation to the malleoli from full dorsiflexion to plantarflexion, whereas lesions within the tendon move with ankle motion. There is often a discrete nodule, whose tenderness significantly decreases or disappears when the tendon is put under tension.⁷¹

ROYAL LONDON HOSPITAL TEST

Once the tester has elicited local tenderness by palpating the tendon with the ankle in neutral position (Fig. 1A) or

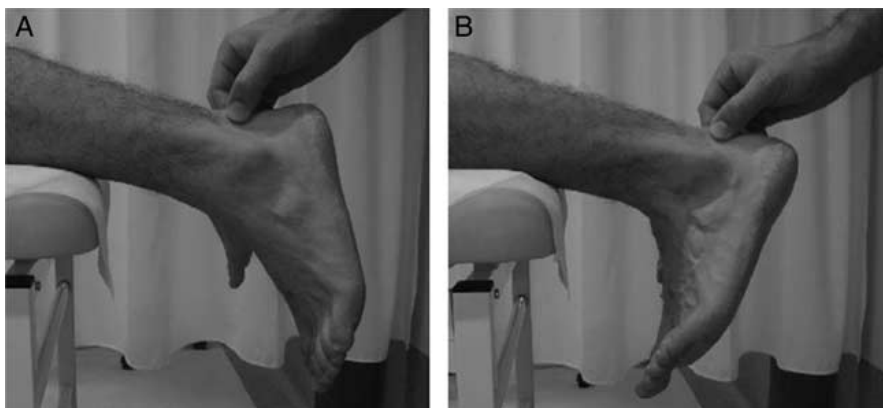


FIGURE 1. Royal London Hospital Test: Once the tester has elicited local tenderness by palpating the tendon with the ankle in neutral position (Fig. 1A), the patient is asked to actively dorsiflex the ankle and to actively plantarflex it. With the ankle in maximum dorsiflexion and in maximum plantarflexion, the portion of the tendon originally found to be tender is palpated again (Fig. 1B).

slightly plantarflexed, the patient is asked to actively dorsiflex the ankle and to actively plantarflex it. With the ankle in maximum dorsiflexion and in maximum plantarflexion, the portion of the tendon originally found to be tender is palpated again (Fig. 1B). Results are classified as tenderness present on dorsiflexion or absent. In asymptomatic tendons, the test is performed selecting an area in the tendon 3 cm proximal to its calcaneal insertion when the ankle is held in neutral.

We evaluated the sensitivity, specificity, reproducibility, and predictive value of palpation, of the painful arc sign and of the Royal London Hospital test.²⁶ In patients with tendinopathy of the AT with a tender area of intratendinous swelling that moves with the tendon and whose tenderness significantly decreases or disappears when the tendon is put under tension, a clinical diagnosis of tendinopathy can be formulated, with a high positive predictive chance that the tendon will show ultrasonographic and histologic features of tendinopathy.

IMAGING

Although plain soft tissue radiography is no longer the imaging modality of choice in tendon disorders, it still has a role in diagnosing associated or incidental bony abnormalities. Magnetic resonance imaging (MRI) provides extensive information about the internal morphology of tendon and the external anatomy (Fig. 2). It is a useful tool to evaluate the various stages of chronic degeneration and differentiation between paratendinopathy and tendinopathy of the main body of the tendon. Areas of mucoid degeneration in the AT are shown at MRI as high signal intensity zone on T1 and T2 weighted images.

MRI is superior to ultrasound (US) in detecting incomplete tendon rupture. However, owing to the high sensitivity of MRI, the data should be interpreted with caution and correlated to the patient symptoms before making any recommendations.⁵¹ Ultrasonography is considered to be operator-dependent, but it correlates well with histopathologic

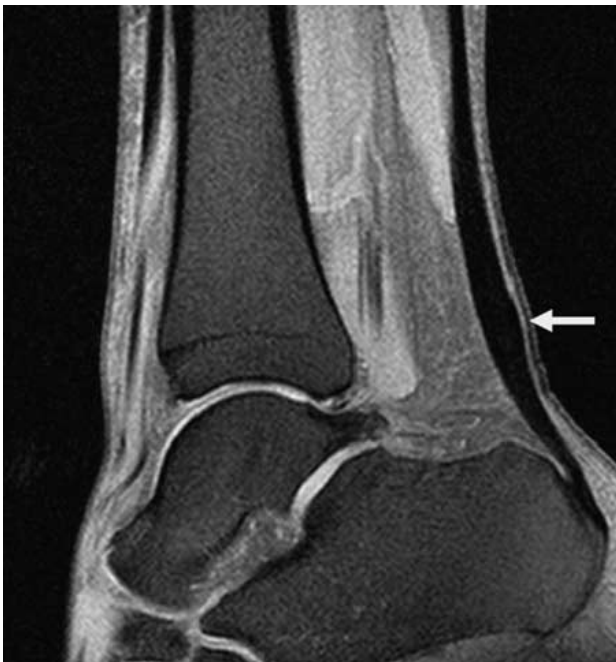

FIGURE 2. Magnetic resonance imaging showing tendinopathy of the main body of the Achilles tendon.

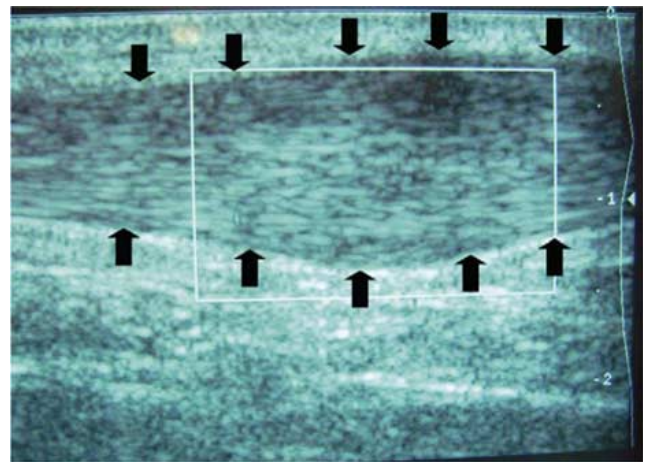


FIGURE 3. Ultrasound view showing thickening of the Achilles tendon.

finding,⁷² and especially in Europe, it is regarded as a primary imaging method (Fig. 3). Thickening of the AT is easily detected with both methods. Only if US remain unclear, an additional magnetic resonance study should be performed and, together with the clinical diagnosis, indications for surgery can be made more efficiently.⁷³ One of the main advantages of US over other imaging modalities is the interactive facility, which helps reproducing symptom by transducers compression and concentrate on the pathologic area.⁷⁴ Although US can demonstrate alterations in the AT with high specificity and sensitivity it has, like MRI, a relatively high incidence of false positive findings.⁷⁵

In a cross-sectional study on badminton players,⁷⁶ doppler flow was not associated with AT pain but with an increased anteroposterior tendon diameter (an indicator of tendinopathy). Athletes who had been playing badminton for longer were more likely to have Doppler flow, and there was a trend toward an association between a greater number of badminton playing hours per week and Doppler flow. The authors concluded that AT Doppler flow seemed to be a sign of asymptomatic tendinopathy rather than pain among active athletes. The association between weekly badminton hours and badminton years and Doppler flow suggested that Doppler flow may be a response to mechanical load.

Victorian Institute of Sports Assessment-Achilles

To be in a position to practice evidence-based medicine, the sports medicine community must conduct studies with objective outcome measures. We developed and tested the Victorian Institute of Sports Assessment-Achilles (VISA-A), a questionnaire-based instrument to measure the severity of Achilles tendinopathy.⁷⁷ To develop the questionnaire, we performed item generation, item reduction, item scaling, and pretesting. We then tested its validity and reliability in clinical and control populations. The VISA-A questionnaire contained 8 questions that covered the 3 domains of pain (questions 1 to 3), function (questions 4 to 6), and activity (questions 7 and 8.)

Questions 1 to 7 are scored out of 10, and question 8 carries a maximum of 30. Scores are summed to give a total out of 100. An asymptomatic person would score 100. For question 8, participants must answer only part A, B, or C. If the participant has pain when undertaking sport, he or she automatically loses at least 10, and possibly 20, points.

The VISA-A questionnaire provides a valid, reliable, and user-friendly index of the severity of Achilles

tendinopathy. Although the limited time for consultation in routine clinical practice means that the main role of this tool is likely to be as an outcome measure in treatment studies, the VISA-A scale can be easily administered in clinical practice. The VISA-A has been cross-cultural adapted to Swedish⁷⁸ and Italian.⁷⁹

MANAGEMENT

Conservative Management of Tendinopathy of the Main Body of Tendo Achillis

Over the past few years, various new therapeutic options have been proposed for the management of Achilles tendinopathy. Despite the morbidity associated with Achilles tendinopathy in athletes, management is far from scientifically based, and many of the therapeutic options described and in common use are lacking a hard scientific background.^{32,80}

Physical therapy, rest, training modification, splintage, taping, cryotherapy, electrotherapy, shock wave therapy, hyperthermia, pharmaceutical agents such as nonsteroidal anti-inflammatory drugs (NSAIDs) and various peritendinous injections have been proposed. Most essentially follow the same principles. Managements that have been investigated with randomized controlled trials include nonsteroidal anti-inflammatory medication, eccentric exercise, glyceryl trinitrate patches, electrotherapy (microcurrent and microwave), sclerosing injections, and shock wave treatment. Surgery should be reserved to patients in whom conservative management has proved ineffective for at least 6 months.

Despite this abundance of therapeutic options, very few randomized prospective, placebo, controlled trials exist to assist in choosing the best evidence-based management.⁸¹ There are no randomized or prospective studies that compare different conservative and surgical management regimens.

NSAIDs

Pharmacologic management strategies are essentially based on empirical evidence. Even though tendon biopsies show an absence of inflammatory cell infiltration,^{19,20} anti-inflammatory agents (NSAIDs and corticosteroids) are commonly used. What may seem clinically as an "acute tendinopathy" is actually a well-advanced failure of a chronic healing response in which there is neither histologic nor biochemical evidence of inflammation.

NSAIDs inhibit tissue inflammation by repressing cyclooxygenase (COX) activity; with a reduction in the synthesis of proinflammatory prostaglandins.⁸² Management of an anatomically defined medical condition is ideally based on an understanding of its pathophysiology. Although, as noted earlier, tendinopathy has a noninflammatory basis, NSAIDs are widely used in attempts as a treatment.⁸³ Ironically, the analgesic effect of NSAIDs⁸⁴ allows patients to ignore early symptoms, possibly imposing further damage on the affected tendon and delaying definitive healing.

Topical naproxen gel produced a marginal advantage in relieving symptoms after 3 and 7 days in patients with acute tendinopathies who had symptoms for less than 48 hours.⁸⁵ Although NSAIDs may provide some pain relief in such patients, they do not actually result in sustained improvement in the healing process.⁸⁶ It is still not known whether NSAIDs actually change the natural history of Achilles tendinopathy or whether they merely exert an analgesic action.⁸⁶ Recent studies on rats with acute tendon

injuries show that NSAID administration does not prevent collagen degradation and loss of tensile force in tendons.⁸⁷ It is therefore questionable whether NSAIDs should be used to alleviate pain in so-called acute tendinopathy.⁸⁷

NSAIDs are not effective in athletes with Achilles tendinopathy.⁸⁸ Most studies of NSAID treatment of tendinopathy have a short follow-up.⁸⁶ Double blind, randomized, placebo-controlled clinical trials of NSAIDs used in the management of tendinopathies based on clinical symptoms and signs only have shown no beneficial effects.⁸⁹ Even these placebo-controlled clinical studies are difficult to interpret because of the inability to control for the severity of the lesion, level of athletic participation, and other variables. NSAIDs could theoretically benefit patients with tendinopathy by increasing the tensile strength of tendons via accelerated formation of cross-linkages between collagen fibers.^{88,90} In animal models, COX inhibitors do show a beneficial effect on tendon regeneration after transection, in exactly this fashion.⁹¹ However, these studies were conducted on rats with tendo Achillis that had been surgically divided, a situation that does not reflect the conditions encountered in chronic tendinopathy. Another study using a rat model showed that, in the first few days after tendo Achillis transection, the inflammatory response was necessary for normal repair, and should not be inhibited.⁹² Early NSAID administration led to a reduction in the amount of force and stress required for the tendon to fail.⁹² During remodeling, on the other hand, inflammation has a negative influence, and NSAIDs such as COX-2 inhibitors might be valuable for the final outcome.⁹² Indeed, late treatment with COX-2 inhibitors leads to increased tensile strength, although they do not change the histopathologic picture.⁹² COX-2 inhibitors should therefore be avoided in the early period after tendon injury, given their deleterious effect on tensile strength.

Although *in vitro* studies on human tendon fibroblasts treated with NSAIDs have shown a decreased expression of prostaglandin E₂, they also show an increased expression of leukotriene B₄.⁹³ The reduction in prostaglandin E₂ may give patients some pain relief; increased leukotriene B₄, however, could potentially exacerbate the situation via increased neutrophilic infiltration and lymphocyte activation,⁹⁴ paradoxically causing inflammatory and degenerative changes in the tendon. Thus, in tendinopathy, leukotriene pathway activation occurs after cyclical strain on tendons, and administration of NSAIDs may actually worsen the condition.

Evidence for the effectiveness of any available drug management regimen is at best controversial when tested in randomized controlled trials.⁴⁶ Pharmacologic management strategies for tendinopathies vary considerably, and are frequently based on empirical evidence. The continued use of NSAIDs for the treatment of tendinopathies is hardly justified. The available literature suggests that, in the absence of an overt inflammatory process, there is no rational basis for the use of NSAIDs in chronic tendinopathy: they are unlikely to change its still ill defined natural history.⁹⁵ Despite this reality, many clinicians still anticipate a quicker and better recovery using these agents. There is no biologic basis for NSAID effectiveness in treating this condition, and no evidence of any benefit. NSAIDs seem to be effective, to some extent, for pain control. Early NSAIDs administration after an injury may have a deleterious effect on long-term tendon healing. It would thus seem reasonable to shift our research efforts to other forms of conservative

management. Examining strategies that promote the migration and activation of tenocytes to influence tendon healing and function might be an appropriate first step. It is equally appropriate to limit our use of NSAIDs in the management of tendinopathy. What may seem clinically as an “acute tendinopathy” is actually a well-advanced failure of a chronic healing response in which there is neither histologic nor biochemical evidence of inflammation.

Clearly there is a controversy on whether NSAIDs help or hinder the healing process. However, most commonly they do provide pain relief, the one thing the patient consults a physician for. Therefore a careful balance between the underlying pathophysiologic condition being managed and the patient’s subjective concerns for pain relief should be considered.

Cryotherapy

Cryotherapy has been regarded as a useful intervention in the acute phase of Achilles tendinopathy, as it has an analgesic effect, reduces the metabolic rate of the tendon, and decreases the extravasation of blood and protein from new capillaries found in tendon injuries.⁹⁶ However, recent evidence in upper limb tendinopathy indicates that the addition of ice did not offer any advantage over an exercise program consisting of eccentric and static stretching exercises.⁹⁷

Eccentric Exercise

Scandinavian authors have shown that, in their hands, a program of eccentric exercise is effective in the non-operative management of tendinopathy.⁹⁸ A program of eccentric exercise has been proposed to counteract the failed healing response which apparently underlies tendinopathy, by promoting collagen fiber cross-linkage formation within the tendon, thereby facilitating tendon remodeling.⁹⁵ Although evidence of actual histologic adaptations after an adapted program of eccentric exercise are lacking, and the mechanisms by which a program of eccentric exercise may help to resolve the pain of tendinopathy remain unclear, clinical results after such exercise program seem promising.^{95,99} Though effective in Scandinavian population,^{99,100} the results of eccentric exercises observed from other study groups^{101,102} are less convincing than those reported from Scandinavia, with a 50% to 60% of good outcome after a regime of eccentric training both in athletic and sedentary patients. In general, the overall trend suggested a positive effect of an exercise program, with no study reporting adverse effects. In a longitudinal study of 34 sedentary patients (18 males, average age 44 y, range: 23 to 67; 16 females, average age 51 y, range: 20 to 76; average BMI: 28.6 ± 4.7, range: 22.1 to 35.4) with a clinical diagnosis of unilateral tendinopathy of the main body of the AT, the patients underwent a graded progressive eccentric calf strengthening exercises program for 12 weeks. Fifteen patients (44%) did not improve with eccentric exercise regimen. Three patients improved after peritendinous injections of aprotinin and local anesthetic. Surgery was performed in 7 patients as 6 months of conservative management failed to produce improvements. The overall average VISA-A scores at latest follow-up was 50 (SD 26.5). Eccentric exercises, though effective in nearly 60% of our patients, may not benefit sedentary patients to the same extent reported in athletes. A further study in 45 athletic patients (29 men, average age 26 y ± 12.8, range: 18 to 42; 16 women, average age 28 y ± 13.1, range: 20 to 46; average

height: 173 ± 16.8, range: 158 to 191; average weight 70.8 kg ± 15.3, range: 51.4 to 100.5) showed that only 27 of the 45 patients responded to the eccentric exercises. Of the 18 patients who did not improve with eccentric exercises, 5 (mean age 33 y) improved with 2 peritendinous aprotinin and local anesthetic injections. Ten of the 18 patients (9 men, mean age 35 y; 1 woman aged 40 y) who did not improve with eccentric exercises and aprotinin injections proceeded to have surgery. The remaining 3 patients (3 women, mean age 59.6 y; 2 men, mean age 63 y) of the 18 nonresponders to eccentric exercises and aprotinin injections declined surgical intervention.

Owing to the lack of high-quality studies with clinically significant results, no strong conclusions can be made regarding the effectiveness of eccentric training (compared with control interventions) in relieving pain, improving function or achieving patient satisfaction.

Treatment effects are found to be overestimated in low quality systematic reviews where nonrandomized studies such as prospective cohorts are included. This may be due to nonrandomization and inadequate allocation concealment methods contained within these prospective studies.

The treatment regime most commonly used is derived from an initial study of Achilles tendinopathy. This comprised 3 sets of 15 repetitions, carried out twice daily, 7 days a week for 12 weeks. It was found that the regime was based on clinical experience, rather than derived from any empirical evidence; for example, data from “dose response”-type studies¹⁰³ (Fig. 4A–H).

However, the lack of understanding about the basic pathophysiology of tendinopathy makes determining the optimal dosage of intervention difficult. Because the studies in this area have not used an underlying rationale to determine loading parameters, progressions and frequency of treatment, further research needs to be undertaken before an optimal dosage can be determined.^{104,105}

We performed a randomized controlled trial in whom we compared the efficacy of 3 protocols—a wait-and-see’ approach, repetitive low-energy shock wave therapy, and eccentric calf strengthening—for the management of chronic tendinopathy of the main body of the tendo Achillis. We concluded that spontaneous recovery after more than 6 months of symptoms of tendinopathy of the main body of the tendo Achillis is unlikely in the majority of patients. The likelihood of recovery after 4 months was comparable after both eccentric loading and shock wave therapy, as applied. Success rates were in the region of 60% with either of these management modalities. Eccentric training or shock wave therapy should be offered to patients with chronic recalcitrant tendinopathy of the main body of tendo Achillis as an alternative to surgery.

Combined management strategies (eccentric training and shock wave therapy) resulted in even higher success rates compared to eccentric loading alone or shock wave therapy alone in a recent randomized controlled trial.¹⁰⁶ Eccentric training plus shock wave therapy should be offered to patients with chronic recalcitrant tendinopathy of the main body of the AT.¹⁰⁶

Nitric Oxide

Nitric oxide is a small-free radical generated by a family of enzymes, the nitric oxide synthases. In a series of experiments performed over the last 15 years, nitric oxide played a crucial beneficial role in restoring tendon function.¹⁰⁷ Free radicals are atoms or molecules with an

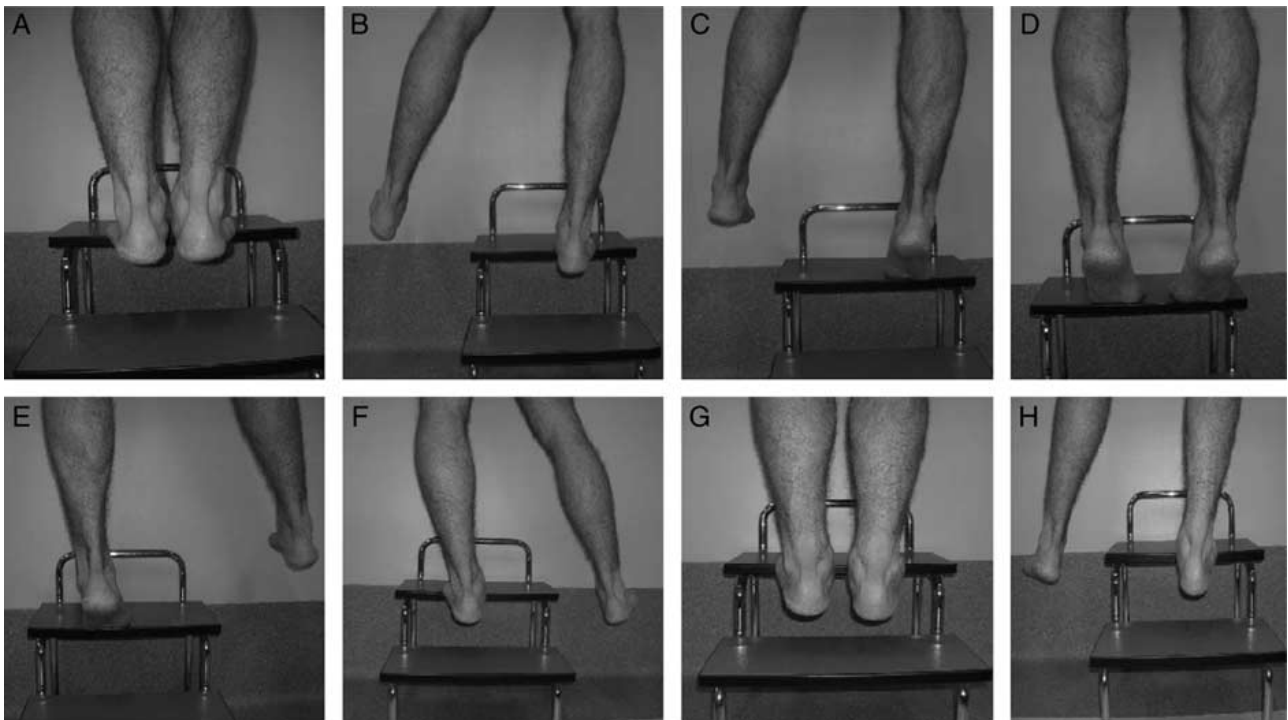


FIGURE 4. Figures from A to H show the sequence of the eccentric training.

unpaired electron. The absence of an electron makes them highly unstable and highly reactive. In biology, in large doses, oxygen free radicals are toxic. Oxygen free radicals, for instance, are responsible in large part for the catabolic effects of ischemia-reperfusion injury, for radiation damage, and for the toxic effects of ultraviolet light. All organisms, including human beings, have developed mechanisms including enzymatic scavengers to protect against free radical damage. Perhaps because free radicals have been present for so long, many organisms have adapted these for other purposes, and, in lower physiologic doses, free radicals can be very effective messenger molecules.¹⁰⁸

Oxygen free radicals, in the correct dose, stimulated fibroblast proliferation. Nitric oxide can enhance tendon healing. Nitric oxide is 1 of the 10 smallest molecules. Its size and its high reactivity allow it to travel across nearly all biologic structures and to readily react with other atoms or molecules to effect a change. Recently, a prospective, randomized, double-blinded, placebo-controlled clinical trial was performed in patients with tendinopathy of the main body of the Achilles to evaluate the efficacy of nitric oxide administration via an adhesive patch.¹⁰⁹ Topical glyceryl trinitrate was demonstrated efficacy in treating chronic noninsertional Achilles tendinopathy, and the treatment benefits continue at 3 years.¹⁰⁸ Significant differences in asymptomatic patient outcomes for the glyceryl trinitrate group continue at 3 years, and this is confirmed by the effect size estimate. This suggests that the mechanism of action of topical glyceryl trinitrate on chronic tendinopathies is more than an analgesic effect.¹⁰⁸

However, a recent study¹¹⁰ failed to support the clinical benefit of topical glyceryl trinitrate patches. There did not seem to be any histologic or immunohistochemical change in Achilles tendinopathy treated with topical glyceryl trinitrate compared with those undergoing standard non-operative therapy.

Intratendinous Injection

Sonographically guided intratendinous injection of hyperosmolar dextrose yielded a good clinical response in patients with chronic tendinopathy of the tendo Achillis.^{111,112}

Sclerosing Injections and Neovascularization

In patients with chronic painful tendinopathy of tendo Achillis, but not in normal pain-free tendons, there is neovascularization outside and inside the ventral part of the tendinopathic area. During eccentric calf muscle contraction, the flow in the neovessels disappears on ankle dorsiflexion.^{113,114} The good clinical effects with eccentric training may be due to action on the neovessels and accompanying nerves. Also, local anesthetic injected in the area of neovascularization outside the tendon resulted in a pain-free tendon, indicating that this area is involved in pain generation. The above findings are the bases for a novel management modality whereby the sclerosing substance polidocanol under US and color Doppler-guidance is injected targeting the area with neovessels and nerves outside the tendon. Rehabilitation after sclerosing injections includes a short period of rest (1 to 3 d), followed by gradual increase of tendon loading activities, but no maximum loading (jumping, fast runs, heavy strength training) for the 2 weeks. After this period, normal tendon loading is allowed.

High Volume US-Guided Injections

The etiology of pain in tendinopathy is widely debated, with recent evidence that neovascularization and neo-innervation may be responsible.¹¹⁵ Neovascularization is mainly present in patients with tendinopathy, and the area in which patients perceive most pain correlates with the area where most neovascularization occurs on power Doppler US.¹¹⁵

We conducted a pilot study in patients with tendinopathy of the main body of tendo Achillis.¹¹⁶ A high volume

image guided tendo Achillis injection of normal saline in patients with resistant Achilles tendinopathy decreased the amount of pain perceived by patients, whereas at the same time by improving daily functional ankle and Achilles movements in the short-term and long-term.

Physical Modalities

The role of physical modalities in the management of tendinopathies remains unclear, and it is not possible to draw firm, evidence-based conclusions on their effectiveness.

Low-energy shock wave therapy to address the failed healing response of a tendon is not widely known among the medical community. A shock wave is defined as an acoustic wave at the front of which pressure rises from the ambient value to its maximum within a few nanoseconds.¹¹⁷ Typical characteristics are high peak-pressure amplitudes (500 bar) with rise times of <10 ns, a short lifecycle (10 ms) and a frequency spectrum (from 16 Hz to 20 MHz) ranging from the audible to the far ultrasonic level.¹¹⁸ This rapid rise is followed by periods of pressure dissipation and negative pressure before gradually returning to the ambient pressure. The shock wave entering the tissue may be reflected or dissipated, depending on the properties of the tissue. The energy of the shock wave may act through mechanical forces generated directly or indirectly via cavitation.¹¹⁸ The rationale for its clinical use being stimulation of soft tissue healing and inhibition of pain receptors, and hence, shock wave therapy has been thoroughly investigated experimentally during the past decade.

There is no consensus on the use of repetitive low-energy shock wave therapy, which does not require local anesthesia, and on the use of high-energy shock wave therapy, which requires local or regional anesthesia.¹⁰¹ Low-energy shock wave therapy has been used in patients with chronic tendinopathy. The randomized controlled trials on this subject are statistically and clinically heterogeneous, thus making conclusions from pooled metaanalyses difficult to interpret. We have tested low energy shock wave therapy for chronic tendinopathy of the main body of the tendon Achillis using a randomized controlled trial design.¹¹⁹ Low energy shock wave therapy and eccentric training produced comparable results, and both management modalities showed outcomes superior to the wait-and-see policy. The likelihood of recovery after 4 months was comparable after both eccentric loading and shock wave therapy, but success rates were from 50% to 60%.

Hyperthermia induced by microwave diathermy raises the temperature of deep tissues from 41 to 45°C using electromagnetic power.¹¹⁹ Microwave diathermy has been used physical medicine and sports traumatology in Central and Southern Europe. Hyperthermia induced into tissue by microwave diathermy can stimulate repair processes, increase drug activity, allow more efficient relief from pain, help removal toxic wastes, increase tendon extensibility and reduce muscle and joint stiffness.¹¹⁹ The biologic mechanisms that regulate the relationship between the thermal dose and the healing process of soft tissues with low or high water content or with low or high blood perfusion are unknown. A recent randomized controlled trial in athletes showed that hyperthermia is effective in the management of established supraspinatus tendinopathy.¹²⁰ This modality warrants further studies with a greater number of patients and a longer-term follow-up to confirm its therapeutic effectiveness. Nevertheless, adequately designed prospective-controlled clinical studies need to be completed to

confirm the therapeutic effectiveness of hyperthermia with large number of patients, longer-term follow-up and mixed populations. It is possible that it only exerts a relatively short lived, but nevertheless useful, analgesic effect.

Ultrasound therapy is a widely available and frequently used electrophysical agent in sports medicine. However, systematic reviews and meta-analyses have repeatedly concluded that there is insufficient evidence to support a beneficial effect of US at dosages currently being introduced clinically. A new direction for US therapy in sports medicine has been proposed by research demonstrating that US can have clinically significant beneficial effects on injured tissue when low-intensity pulsed US is used.¹²⁰ Low-intensity pulsed US refers to pulsed-wave US with a spatial-averaged, temporal-averaged intensity equal to or lower than 100 mW/cm². This intensity is categorized as low relative to the range that is commonly used in physical therapy (from 0.5 to 2 W/cm²).¹²⁰ Low-intensity pulsed US has been shown to be beneficial in accelerating fracture healing in clinical studies and to stimulate union in 86% of fractures displaying nonunion.¹²⁰ Although established in the intervention of bone injuries, recent efforts have been directed toward the effect of low-intensity pulsed US on injuries to other connective tissues.¹²¹ Low-intensity pulsed US therapy has been tested in a randomized, double-blind, placebo-controlled trial in patients with chronic lateral epicondylitis.⁴⁵ It was no more effective for a large treatment effect than placebo for recalcitrant lateral epicondylitis.

Summary of Nonoperative Management of Achilles Tendinopathy

Pharmacologic management strategies are essentially based on empirical evidence. Even though they are not proved for the management of Achilles tendinopathy, their use is controversy, because they do provide pain relief, the one thing the patient consults a physician for. In our clinical practice commonly we do not prescribe NSAIDs. Cryotherapy has been regarded as a useful intervention in the acute phase of Achilles tendinopathy, as it has an analgesic effect. A program of eccentric exercise can improve patient's symptoms in nearly 60% of the patients. In general, the overall trend suggested a positive effect of an exercise program, with no study reporting adverse effects. No definitive evidences have been reached for the use of nitric oxide to enhance tendon healing. Sclerosing injections can be an option, but contrasting results have been reported. High volume US-guided injections are a new option of management, and in our clinical practice this is the modality of choice when a program of eccentric training fails to improve patient's symptoms. The role of physical modalities in the management of tendinopathies remains unclear, and it is not possible to draw firm evidence-based conclusions on their effectiveness. There is some evidence that low-energy shock wave therapy is useful to address the failed healing response of a tendon. We also demonstrated a synergistic effect of eccentric training and shock wave therapy.

Surgical Management of Tendinopathy of the Main Body of Tendo Achillis

In 24% to 45.5% of patients with Achilles tendinopathy, conservative management is unsuccessful, and surgery is recommended after exhausting conservative methods of management, often tried for at least 6 months.^{25,122} However, long-standing Achilles tendinopathy is associated with

poor postoperative results, with a greater rate of reoperation before reaching an acceptable outcome.¹²³

The objective of surgery is to excise fibrotic adhesions, remove areas of failed healing and make multiple longitudinal incisions in the tendon to detect intratendinous lesions and to restore vascularity and possibly stimulate the remaining viable cells to initiate cell-matrix response and healing.⁹⁶ Recent studies show that multiple longitudinal tenotomies trigger neoangiogenesis at the tendo Achillis, with increased blood flow.¹²⁴ This would result in improved nutrition and a more favorable environment for healing. Patients are encouraged to weight bear as soon as possible after surgery.

Most authors report excellent or good results in up to 85% of cases, although this is not always observed in routine nonspecialized clinical practice. It is difficult to compare the results of studies, as most investigations do not report their assessment procedure. Also, no prospective randomized studies comparing operative and conservative treatment of Achilles tendinopathy have been published, thus most of our knowledge on treatment efficacy is on the basis of clinical experience and descriptive studies.

It is still debatable why tendinopathic tendons respond to surgery. For example, we do not know whether surgery induces long-term revascularization, denervation or both, resulting in pain reduction. It is also unclear exactly how longitudinal tenotomy improves vascularization. Proximal to its calcaneal insertion, the AT lies immediately superficial to the pre-Achilles fat pad, a triangular area of adipose tissue known as Kager's triangle.

We introduced a new minimally invasive stripping of neovessels from the Kager's triangle of the tendo Achillis for patients with Achilles tendinopathy.¹²⁵ This achieves a safe and secure breaking of neovessels and the accompanying nerve supply.

MINIMALLY INVASIVE STRIPPING

In chronic painful tendinopathy of tendo Achillis, but not in normal pain-free tendons, there is neovascularization outside and inside the ventral part of the tendinopathic area.^{31,35,126-128} During eccentric calf muscle contraction, the flow in the neovessels disappears on ankle dorsiflexion. The good clinical effects with eccentric training may be due to action on the neovessels and accompanying nerves.^{31,35,126,127} Classically, open surgery for tendinopathy of the main body of the AT has provided good results.³¹ However, wound complications can occur with these procedures, and recovery is prolonged.²⁵

We have developed a novel management modality whereby a minimal invasive technique of stripping of

neovessels from the Kager's triangle of the AT is performed. This achieves a safe and secure breaking of neovessels and the accompanying nerve supply.

The patient undergoes local or general anesthesia, according to surgeon's or patient's preferences. The patient is positioned prone with a calf tourniquet that is inflated to 250 mm Hg after exsanguination. Four skin incisions are made. The first 2 incisions are 0.5 cm longitudinal incisions at the proximal origin of the AT, just medial and lateral to the origin of the tendon. The other 2 incisions are also 0.5 cm long and longitudinal, at the level of the tendon insertion on the calcaneus.

Mosquito forceps or a tendon passer is inserted in the proximal incisions (Fig. 5A), and the AT is freed of the peritendinous adhesions. A number 1 unmounted Ethibond (Ethicon, Somerville, NJ) suture thread is inserted proximally, passing through the 2 proximal incision. The Ethibond is retrieved from the distal incisions (Fig. 5B), over the posterior aspect of the AT. Using a gentle see-saw motion, similar to using a Gigli saw, the Ethibond suture thread is made to slide posterior to the tendon (Fig. 5C), which is stripped and freed from the fat of Kager's triangle.

Our minimal invasive technique reduce the risks of infection, is technically easy to master, and inexpensive. It may provide greater potential for the management of recalcitrant AT by breaking neovessels and the accompanying nerve supply to the tendon. It can be associated with other minimally invasive procedures to optimize the results.

The pathogenetic significance of the neovascularization is unknown, but several theories can be proposed. The increased vascularization often seen in biopsies from patients with chronic painful tendinopathy of tendo Achillis who underwent surgery is a part of a reparative response in the tendon.^{128,129} Reparative processes associated with neovascularization are probably inadequate.^{25,126} Surgery is successful in up to 85% of patients,²⁵ even though postoperative US examination often shows a widened tendon with hypo-echoic areas. This has led to hypotheses of a possible denervation of the tendon as one of the explanations to the frequently favorable effect of surgery.¹³⁰

Our rationale behind the present management modality is that the sliding of the Ethibond breaks the neovessels and the accompanying nerve supply, therefore decreasing the pain in patients with chronic Achilles tendinopathy.

Percutaneous Longitudinal Tenotomy

We have used multiple percutaneous longitudinal tenotomies when conservative management has failed in patients with isolated tendinopathy with no involvement of

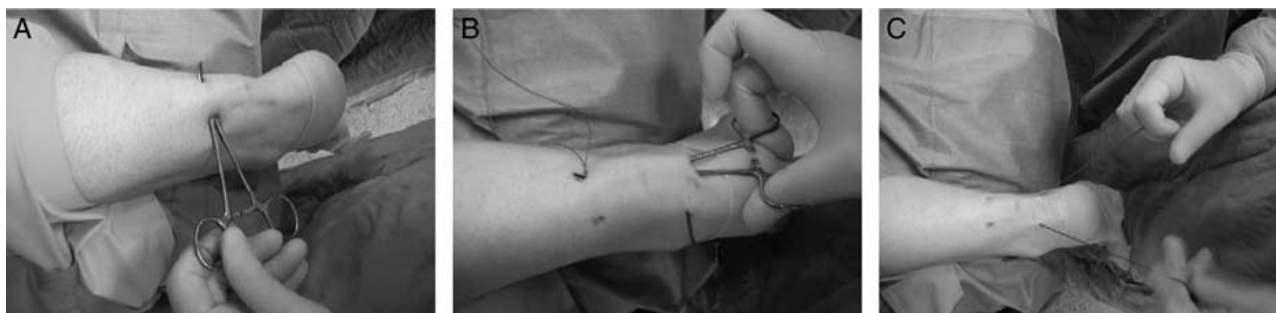

FIGURE 5. A mosquito is inserted in the proximal incisions (Fig. 5A). The Ethibond is retrieved from the distal incisions (Fig. 5B). The Ethibond is slid over the anterior aspect of the Achilles tendon with a gentle see-saw motion (Fig. 5C).

the paratenon and a well-defined nodular lesion less than 2.5 cm long.⁴⁵ US can be used to confirm the precise location of the area of tendinopathy. If the multiple percutaneous tenotomies are performed in the absence of chronic paratendinopathy, the outcome is comparable to that of open procedures. It is a simple procedure and can be performed in the clinic under local anesthesia without a tourniquet, but attention to detail is necessary, as even in minimally invasive procedures complications are possible.

Percutaneous longitudinal US-guided internal tenotomy of the tendo Achilles is simple and can be performed on an outpatient basis. It, however, requires the use of high-resolution US to properly locate the tendinopathic area and to place the initial stab wound. Also, with this technique, it is not possible to collect samples of tendon material for biopsy, even though recent work has shown that symptomatic intratendinous areas are hypo-echoic at US show tendinosis. Complications were minimal and led to no long-term morbidity. In our hands, it is an intervention in the management of chronic Achilles tendinopathy when conservative treatment has failed. The technique is not as effective in patients with paratendinopathy.

Operative Technique

The patient lies prone on the examination couch with the feet protruding beyond the edge, and the ankles resting on a sandbag. A bloodless field is not necessary. The tendon is accurately palpated, and the area of maximum swelling and/or tenderness marked, and checked by US scanning. The skin is prepped with an antiseptic solution, and a sterile longitudinal 7.5-MHz probe is used to image again the area of tendinopathy. Before infiltrating the skin and the subcutaneous tissues over the tendo Achilles with 10 mL of 1% lignocaine (Pierrel, Milan, Italy), 7 mL of 0.5% lignocaine is used to infiltrate the space between the tendon and the paratenon, to try and distend the paratenon and break the adhesences that may be present between the tendon and the paratenon. Under US control, a number 11 surgical scalpel blade (Swann-Morton, London, UK) is inserted parallel to the long axis of the tendon fibers in the center of the area of tendinopathy, as assessed by high-resolution US imaging. The cutting edge of the blade points caudally and penetrates the whole thickness of the tendon.

Although keeping the blade still, a full passive ankle flexion is produced. The scalpel blade is then retracted to the surface of the tendon and inclined 45 degree on the sagittal axis, and the blade is inserted medially through the original tenotomy. Although keeping the blade still, a full passive ankle flexion is produced. The whole procedure is repeated inclining the blade 45 degree laterally to the original tenotomy, inserting it laterally through the original tenotomy. Although keeping the blade still, a full passive ankle flexion is produced. The blade is then partially retracted to the posterior surface of the tendo Achilles, reversed 180 degree, so that its cutting edge now points caudally, and the whole procedure repeated, taking care to dorsiflex the ankle passively. A Steristrip (3M United Kingdom PLC, Bracknell, Berkshire, UK) can be applied on the stab wound, or the stab wound can be left open. The wound is dressed with cotton swabs, and a few layers of cotton wool and a crepe bandage are applied.

OPEN SURGERY

Surgical Technique

The prone position allows excellent access to the affected area. Alternatively, the patient can be positioned

supine with a sandbag under the opposite hip and the affected leg positioned in a figure-of-four position. Open surgery for tendinopathy of the main body of the tendo Achilles involves a longitudinal incision. Generally the incision is made on the medial side of the tendon to avoid injury to the sural nerve and short saphenous vein. A straight posterior incision may also be more bothersome with the edge of the heel counter pressing directly on the incision. Preoperative imaging studies can guide the surgeon in the placement of the incision. The skin edge of the incision should be handled with extreme care throughout the procedure, as wound-healing problems are possible and potentially disastrous. The paratenon is identified and incised. In patients with evidence of coexisting paratendinopathy, the scarred and thickened tissue is generally excised. Care should be taken to minimize dissection and excision on the anterior side of the tendon. The fatty tissue anteriorly is thought to contain much of the vascular supply to the tendon. On the basis of preoperative imaging studies, the tendon is incised sharply in line with the tendon fiber bundles. The tendinopathic tissue can be identified as it generally has lost its shiny appearance, and frequently contains disorganized fiber bundles that have more of a "crabmeat" appearance. This tissue is sharply excised. The remaining gap can be repaired using a side-to-side repair. If significant loss of tendon tissue occurs during the debridement, consideration could be given to a tendon augmentation or transfer, even though we rarely undertake this additional procedure. A tendon turn-down flap has been described for this purpose. With a turn-down procedure, 1 or 2 strips of tendon tissue from the gastrocnemius tendon is dissected out proximally whereas leaving the strip attached to the main tendon distally. It is then flipped 180 degree and sewn in to cover and bridge the weakened defect in the distal tendon. A plantaris weave has also been reported for this purpose. The plantaris tendon can be found on the medial edge of the tendo Achilles. It can be traced proximally as far as possible and detached as close as possible to the muscle tendon junction to gain as much length as possible. It can be left attached distally to the calcaneus, looped, and weaved through the proximal tendo Achilles and sewn back onto the distal part to the tendon. Alternatively, the plantaris can be detached distally as well and used as a free graft. Finally, transfer and augmentation with the flexor hallucis longus tendon has been reported.²¹

Open surgery for tendinopathy of the main body of the AT can be considered if prolonged nonoperative management fails. However, patients should be informed of the potential failure of the procedure, risks of wound complications and at times prolonged recovery time.¹³¹ The surgical procedure is relatively straightforward, but on occasion may require concomitant transfer of tendon tissue to reinforce the weakened tendon. Rehabilitation is focused on early motion and avoidance of overloading the tendon in the initial healing phase.

Other Operative Techniques

Muscle Transfer to the Body of the Tendon

Longitudinal tenotomies increase the blood supply of the degenerated area. Recently, in a rabbit model, after longitudinal tenotomy we performed a soleus pedicle graft within the operated tendon, and showed that the transplanted muscle was viable and had integrated well within the tendon tissue 3 months after the transplant, without transforming into connective tissue. The transplanted

muscle fibers integrated with the tendon but remained distinct from it. Hypervascularization of the graft tissue, probably owing to the operation, was also observed, together with neoangiogenesis up to 3 months after the operation.¹³²

OUTCOME OF SURGERY

We performed a systematic review of the available published literature covering the years from 1966 to 1999 to identify all studies that reported the outcome of surgery for Achilles tendinopathy as their primary aim.¹³³ Keywords used in the search were tendo Achillis, tendinitis, tendon, postoperative complications, tendon injuries, and tendinopathy. Subheadings used in the search were surgery, pathology, physiology, and imaging. All journals were considered and all relevant articles were retrieved. Most of the articles that reported surgical success rates revealed successful results in over 70% of cases. However, this relatively high success rate is not always observed in clinical practice. The articles that reported success rates higher than 70% actually had poorer methods scores. This finding could be used as evidence that the discrepancy between published and actual outcomes is due to the deficiencies in methods; this also points the way for developing a set of criteria that should be used to plan future surgical studies.

GENETICS

A genetic component has been implicated in tendinopathies involving the AT.^{134,135} An underlying genetic factor as a contributing cause to AT injury was originally proposed because of an association between the ABO blood group and the incidence of AT ruptures or chronic Achilles tendinopathy evident in Hungarian and Finnish populations with blood group O.¹³⁶

The distribution of the ABO and Rh blood groups was determined in 832 patients with a tendon rupture. Among these, the frequency of blood group O (52.8%) was significantly higher than in the general population of Hungary (31.1%) and the frequency of group A was significantly lower. Of the 83 cases of multiple ruptures or rerupture, 57 patients (68.7%) had blood group O. The dominance of group O was found for all sites of tendon rupture, but there was no significant association with the Rh groups. Individuals with blood group O seemed to have an increased risk of tendon rupture.¹³⁶

The distribution of the ABO blood groups was studied in Finland in 917 patients with specific musculoskeletal diagnoses. The ABO blood group distribution of patients with rupture of the AT ($P=0.030$) and of patients with chronic Achilles tendinopathy ($P=0.10$) differed from the controls. The ABO blood group distribution was not associated with other musculoskeletal injuries studied. The blood group A/O ratio was 1.42 in the control population. In the group with rupture of the AT this ratio was 1.0, and in the group with Achilles tendinopathy it was 0.70.¹³⁷ These studies implied that ABO or closely linked genes on the tip of the long arm of chromosome 9 could be associated with tendinopathy or tendon injuries. The gene for ABO on chromosome 9q34 encode for transferases, which apart from determining the structure of glycoprotein antigens on red blood cells, may also determine the structure of some proteins of the ECM of tendons.¹³⁶ To test whether the association between blood groups and AT rupture reported in Finland and in Hungary was present in Scotland, the

distribution of ABO blood groups of 78 patients was compared with that found in 24,501 blood donors typed at the Blood Transfusion Centre during the same period. Overall, 47 of 78 (60%) of patients with an AT rupture belonged to blood group O, compared with 51% of the population as a whole. Only 22 (28%) of the AT rupture patients belonged to blood group A, whereas 35% of the general population were members of this group (NS). The A/O ratio was 0.47 for the tendon rupture patients, compared with 0.68 for the general population. The authors could not demonstrate any significant association between the proportions of ABO blood groups and ATR in the Grampian Region of Scotland.¹³⁸ The findings in other studies could be due to peculiarities in the distribution of the ABO groups in genetically segregated populations.¹³⁸

Polymorphisms within the COL5A1 and tenascin-C (TNC) genes have been associated with AT injuries in a physically active population.^{134,135} The COL5A1 gene, which is in close proximity to the ABO genes on chromosome 9q34¹³⁹ encodes for a structural component of type V collagen which forms heterotypic fibers with type I collagen in tendons and possibly plays an important role in regulating fibrillogenesis and, therefore, tendon strength.^{140,141} COL5A1 gene has a role in the pathogenesis of Achilles tendinopathy and it has been observed that South African individuals with the A2 allele of this gene are less likely to develop Achilles tendinopathy.¹³⁵ Although no direct link with COL5A1 gene has been demonstrated, the genes encoding for collagen I and III, namely COL1A1 and COL3A1, show relatively high but variable levels of expression in normal tendon, and significantly increased expression of both genes in painful tendinopathy.¹⁴² This correlation needs to be investigated further. TNC is a modular and multifunctional ECM glycoprotein that is exquisitely regulated during embryonic development and in adult tissue remodeling.¹⁴³ The TNC gene, which encodes for the ECM glycoprotein TNC in tendons, is also closely linked to the ABO genes on chromosome 9q32 to q34.¹⁴⁴ The TNC gene is expressed in regions of the tendon predominantly responsible for transmitting high levels of mechanical force, such as the myotendinous and osteotendinous junctions,¹⁴⁵ and is regulated by mechanical loading in a dose dependent manner.^{145,146} The TNC protein is involved in regulating cell-matrix interactions.¹⁴⁷ It interacts with fibronectin, aggrecan, versican, brevican, neurocan, integrins, cell adhesion molecules and annexin II.¹³⁴ Allele distribution of the guanine-thymine (GT) dinucleotide repeat polymorphism in the TNC gene is associated with AT injury.¹³⁴ Alleles containing 12 and 14 GT repeats were significantly higher in patients with AT injuries, whereas alleles containing 13 and 17 GT repeats were higher in the asymptomatic controls.¹³⁴ A possible biologic explanation for TNC involvement in the etiology of AT injuries could be explained by abnormal mechanical loading leading to altered synthesis of TNC,¹⁴⁸ which could disrupt the regulation of cell-matrix interactions in the tendon,¹⁴⁷ with the onset of apoptotic changes in the tenocytes.¹⁴⁹ The exact role of COL5A1 and TNC genes in the pathogenesis of tendinopathy is still debated, and the current evidence does not allow to clarify whether or not COL5A1 and TNC genes are the ideal markers of tendinopathy.¹³⁵ A negative association of a particular gene, such as with the ABO system,¹³⁸ does not necessarily mean that there is absolutely no association with that particular gene(s) at that locus. The fact that certain studies have

found an association with the ABO system and tendon injuries^{138,150} warrants further investigation at that particular locus. It is also possible that other genes, yet to be determined, may contribute towards the pathogenesis of tendinopathy, which could be a polygenic condition, given the multitude of the genes involved in maintaining normal tendon homeostasis. On the basis of current evidence, it is difficult to conceive that only a single gene and not multiple genes are involved in the pathogenesis of Achilles tendinopathy. Thus, additional investigation needs to be performed to identify these genes.^{134,135,151}

CONCLUSIONS

Achilles tendinopathy gives rise to significant morbidity, and, at present, only limited scientifically proven management modalities exist. The management of this condition remains a challenge, especially in athletes, in whom the physician often tries to be innovative. In many instances, this carries with it an unquantifiable risk.²⁴ A better understanding of tendon function and healing will allow specific management strategies to be developed.^{64,65,152} Many interesting techniques are being pioneered.^{33,58,66,153} Although these emerging technologies may develop into substantial clinical management options, their full impact needs to be evaluated critically in a scientific fashion. Future trials should use validated functional and clinical outcomes, adequate methodology, and be sufficiently powered. Clearly, studies of high levels of evidence, for instance large randomized trials, should be conducted to help answer many of the unsolved questions in this field.

REFERENCES

- Maffulli N, Khan KM, Puddu G. Overuse tendon conditions: time to change a confusing terminology. *Arthroscopy*. 1998;14:840–843.
- Ames PR, Longo UG, Denaro V, et al. Achilles tendon problems: not just an orthopaedic issue. *Disabil Rehabil*. 2008;30:1646–1650.
- James SL, Bates BT, Osternig LR. Injuries to runners. *Am J Sports Med*. 1978;6:40–50.
- Maffulli N, Binfield PM, King JB. Tendon problems in athletic individuals. *J Bone Joint Surg Am*. 1998;80:142–144.
- Rovere GD, Webb LX, Gristina AG, et al. Musculoskeletal injuries in theatrical dance students. *Am J Sports Med*. 1983;11:195–198.
- Teitz CC, Garrett WE Jr, Miniaci A, et al. Tendon problems in athletic individuals. *Instr Course Lect*. 1997;46:569–582.
- Winge S, Jorgensen U, Lassen Nielsen A. Epidemiology of injuries in Danish championship tennis. *Int J Sports Med*. 1989;10:368–371.
- Astrom M. Partial rupture in chronic achilles tendinopathy. A retrospective analysis of 342 cases. *Acta Orthop Scand*. 1998;69:404–407.
- Kader D, Saxena A, Movin T, et al. Achilles tendinopathy: some aspects of basic science and clinical management. *Br J Sports Med*. 2002;36:239–249.
- Richards PJ, Braid JC, Carmont MR, et al. Achilles tendon ossification: Pathology, imaging and aetiology. *Disabil Rehabil*. 2008;30:1651–1665.
- Maffulli N, Ajjis A, Longo UG, et al. Chronic rupture of tendo achillis. *Foot Ankle Clin*. 2007;12:583–596. vi.
- Ebinesan AD, Sarai BS, Walley GD, et al. Conservative, open or percutaneous repair for acute rupture of the Achilles tendon. *Disabil Rehabil*. 2008;30:1721–1725.
- Stilwell DL Jr. The innervation of tendons and aponeuroses. *Am J Anat*. 1957;100:289–317.
- Jozsa L, Kannus P. Human Tendon: Anatomy. *Physiology and Pathology*. Champaign, IL: Human Kinetics; 1997:573.
- Ippolito E, Natali PG, Postacchini F, et al. Morphological, immunochemical, and biochemical study of rabbit achilles tendon at various ages. *J Bone Joint Surg Am*. 1980;62:583–598.
- Khan KM, Cook JL, Bonar F, et al. Histopathology of common tendinopathies. Update and implications for clinical management. *Sports Med*. 1999;27:393–408.
- Vailas AC, Pedrini VA, Pedrini-Mille A, et al. Patellar tendon matrix changes associated with aging and voluntary exercise. *J Appl Physiol*. 1985;58:1572–1576.
- Langberg H, Skovgaard D, Petersen LJ, et al. Type I collagen synthesis and degradation in peritendinous tissue after exercise determined by microdialysis in humans. *J Physiol*. 1999;521(Pt 1):299–306.
- Longo UG, Franceschi F, Ruzzini L, et al. Histopathology of the supraspinatus tendon in rotator cuff tears. *Am J Sports Med*. 2008;36:533–538.
- Longo UG, Franceschi F, Ruzzini L, et al. Light microscopic histology of supraspinatus tendon ruptures. *Knee Surg Sports Traumatol Arthrosc*. 2007;15:1390–1394.
- Movin T, Gad A, Reinholt FP, et al. Tendon pathology in long-standing achillodynia. Biopsy findings in 40 patients. *Acta Orthop Scand*. 1997;68:170–175.
- Jarvinen M, Jozsa L, Kannus P, et al. Histopathological findings in chronic tendon disorders. *Scand J Med Sci Sports*. 1997;7:86–95.
- Waterston SW, Maffulli N, Ewen SW. Subcutaneous rupture of the Achilles tendon: basic science and some aspects of clinical practice. *Br J Sports Med*. 1997;31:285–298.
- Hamilton B, Remedios D, Loosemore M, et al. Achilles tendon rupture in an elite athlete following multiple injection therapies. *J Sci Med Sport*. 2007.
- Maffulli N, Kader D. Tendinopathy of tendo achillis. *J Bone Joint Surg Br*. 2002;84:1–8.
- Maffulli N, Kenward MG, Testa V, et al. Clinical diagnosis of Achilles tendinopathy with tendinosis. *Clin J Sport Med*. 2003;13:11–15.
- Lippi G, Longo UG, Maffulli N. Genetics and Sports. *Br Med Bull*. 2009. Feb 9. [Epub ahead of print].
- Perugia L, Postacchini F, Ippolito E. *The tendons Biology, pathology, clinical aspects*. Milano: Kurtis; 1986.
- Longo G, Ripalda P, Denaro V, et al. Morphologic comparison of cervical, thoracic, lumbar intervertebral discs of cynomolgus monkey (*Macaca fascicularis*). *Eur Spine J*. 2006;15:1845–1851.
- Maffulli N, Reaper J, Ewen SW, et al. Chondral metaplasia in calcific insertional tendinopathy of the Achilles tendon. *Clin J Sport Med*. 2006;16:329–334.
- Maffulli N, Sharma P, Luscombe KL. Achilles tendinopathy: aetiology and management. *J R Soc Med*. 2004;97:472–476.
- Maffulli N, Testa V, Capasso G, et al. Surgery for chronic Achilles tendinopathy produces worse results in women. *Disabil Rehabil*. 2008;30:1714–1720.
- Sharma P, Maffulli N. Tendon injury and tendinopathy: healing and repair. *J Bone Joint Surg Am*. 2005;87:187–202.
- Magra M, Maffulli N. Genetic aspects of tendinopathy. *J Sci Med Sport*. 2007. [Epub ahead of print].
- Maffulli N, Testa V, Capasso G, et al. Similar histopathological picture in males with Achilles and patellar tendinopathy. *Med Sci Sports Exerc*. 2004;36:1470–1475.
- Burry HC, Pool CJ. Central degeneration of the achilles tendon. *Rheumatol Rehabil*. 1973;75:177–181.
- Harms J, Biehl G, von Hobach G. Pathologie der paratenonitis achillea bei hochleistungssportlern. *Arch Orthop Unfallchir*. 1977;88:65–74.
- Merkel KH, Hess H, Kunz M. Insertion tendinopathy in athletes. A light microscopic, histochemical and electron microscopic examination. *Pathol Res Pract*. 1982;173:303–309.
- Puuddu G, Ippolito E, Postacchini F. A classification of Achilles tendon disease. *Am J Sports Med*. 1976;4:145–150.
- Clancy WGJ, Neidhart D, Brand RL. Achilles tendonitis in runners: a report of cases. *Am J Sports Med*. 1976;4:46–57.

41. Williams JG. Achilles tendon lesions in sport. *Sports Med.* 1993;16:216–220.
42. Denstad TF, Roaas A. Surgical treatment of partial Achilles tendon rupture. *Am J Sports Med.* 1979;7:15–17.
43. Fox JM, Blazina ME, Jobe FW, et al. Degeneration and rupture of the Achilles tendon. *Clin Orthop Relat Res.* 1975;107:221–224.
44. Astrom M, Rausing A. Chronic Achilles tendinopathy. A survey of surgical and histopathologic findings. *Clin Orthop Relat Res.* 1995;316:151–164.
45. Maffulli N, Testa V, Capasso G, et al. Results of percutaneous longitudinal tenotomy for Achilles tendinopathy in middle- and long-distance runners. *Am J Sports Med.* 1997;25:835–840.
46. Magra M, Maffulli N. Nonsteroidal antiinflammatory drugs in tendinopathy: friend or foe. *Clin J Sport Med.* 2006;16:1–3.
47. Kvist M, Jozsa L, Jarvinen M, et al. Fine structural alterations in chronic Achilles paratenonitis in athletes. *Path Res Pract.* 1985;180:416–423.
48. Maffulli N, Barrass V, Ewen SW. Light microscopic histology of achilles tendon ruptures. A comparison with unruptured tendons. *Am J Sports Med.* 2000;28:857–863.
49. Maffulli N, Ewen SW, Waterston SW, et al. Tenocytes from ruptured and tendinopathic achilles tendons produce greater quantities of type III collagen than tenocytes from normal achilles tendons. An in vitro model of human tendon healing. *Am J Sports Med.* 2000;28:499–505.
50. Maganaris CN, Narici MV, Maffulli N. Biomechanics of the Achilles tendon. *Disabil Rehabil.* 2008;30:1542–1547.
51. Leadbetter WB. Cell-matrix response in tendon injury. *Clin Sports Med.* 1992;11:533–578.
52. Johnson KW, Zalavras C, Thordarson DB. Surgical management of insertional calcific achilles tendinosis with a central tendon splitting approach. *Foot Ankle Int.* 2006;27:245–250.
53. Kvist M. Achilles tendon injuries in athletes. *Sports Med.* 1994;18:173–201.
54. Selvanetti A, Puddu G. Overuse tendon injuries: basic science and classification. *Operative Tech Sports Med.* 1997;5:110–117.
55. Bestwick CS, Maffulli N. Reactive oxygen species and tendinopathy: do they matter? *Br J Sports Med.* 2004;38:672–674.
56. Sullo A, Maffulli N, Capasso G, et al. The effects of prolonged peritendinous administration of PGE1 to the rat Achilles tendon: a possible animal model of chronic Achilles tendinopathy. *J Orthop Sci.* 2001;6:349–357.
57. Tallon C, Maffulli N, Ewen SW. Ruptured Achilles tendons are significantly more degenerated than tendinopathic tendons. *Med Sci Sports Exerc.* 2001;33:1983–1990.
58. Sharma P, Maffulli N. Understanding and managing Achilles tendinopathy. *Br J Hosp Med (Lond).* 2006;67:64–67.
59. Magra M, Maffulli N. Molecular events in tendinopathy: a role for metalloproteases. *Foot Ankle Clin.* 2005;10:267–277.
60. Magra M, Caine D, Maffulli N. A review of epidemiology of paediatric elbow injuries in sports. *Sports Med.* 2007;37:717–735.
61. Magra M, Hughes S, El Haj AJ, et al. VOCCs and TREK-1 ion channel expression in human tenocytes. *Am J Physiol Cell Physiol.* 2007;292:C1053–C1060.
62. Magra M, Maffulli N. Matrix metalloproteases: a role in overuse tendinopathies. *Br J Sports Med.* 2005;39:789–791.
63. Maffulli N, Benazzo F. Basic sciences of tendons. *Sports Med Arthrosc Rev.* 2000;8:1–5.
64. Sharma P, Maffulli N. Basic biology of tendon injury and healing. *Surgeon.* 2005;3:309–316.
65. Sharma P, Maffulli N. The future: rehabilitation, gene therapy, optimization of healing. *Foot Ankle Clin.* 2005;10:383–397.
66. Sharma P, Maffulli N. Biology of tendon injury: healing, modeling and remodeling. *J Musculoskelet Neuronal Interact.* 2006;6:181–190.
67. Kumar K, Sharma VK, Sharma R, et al. Correction of cubitus varus by French or dome osteotomy: a comparative study. *J Trauma.* 2000;49:717–721.
68. Magra M, Maffulli N. Genetics: does it play a role in tendinopathy? *Clin J Sport Med.* 2007;17:231–233.
69. Magra M, Maffulli N. Genetic aspects of tendinopathy. *J Sci Med Sport.* 2008;11:243–247.
70. Williams JG. Achilles tendon lesions in sport. *Sports Med.* 1986;3:114–135.
71. Barnes SJ, Gey van Pettius D, Maffulli N. Angioleiomyoma of the achilles tendon. *Bull Hosp Jt Dis.* 2003;61:137–139.
72. Rolf C, Movin T. Etiology, histopathology, and outcome of surgery in achillodynia. *Foot Ankle Int.* 1997;18:565–569.
73. Neuhold A, Stiskal M, Kainberger F, et al. Degenerative Achilles tendon disease: assessment by magnetic resonance and ultrasonography. *Eur J Radiol.* 1992;14:213–220.
74. Gibbon WW. Musculoskeletal ultrasound. *Baillieres Clin Rheumatol.* 1996;10:561–588.
75. Khan KM, Maffulli N. Tendinopathy: an Achilles' heel for athletes and clinicians. *Clin J Sport Med.* 1998;8:151–154.
76. Malliaras P, Richards PJ, Garau G, et al. Achilles tendon doppler flow may be associated with mechanical load among active athletes. *Am J Sports Med.* 2008;36:2210–2215.
77. Robinson JM, Cook JL, Purdam C, et al. The VISA-A questionnaire: a valid and reliable index of the clinical severity of Achilles tendinopathy. *Br J Sports Med.* 2001;35:335–341.
78. Silbernagel KG, Thomee R, Karlsson J. Cross-cultural adaptation of the VISA-A questionnaire, an index of clinical severity for patients with Achilles tendinopathy, with reliability, validity and structure evaluations. *BMC Musculoskelet Disord.* 2005;6:12.
79. Lippi G, Banfi G, Favalaro EJ, et al. Updates on improvement of human athletic performance: focus on world records in athletics. *Br Med Bull.* 2008;87:7–15.
80. Maffulli N, Walley G, Sayana MK, et al. Eccentric calf muscle training in athletic patients with Achilles tendinopathy. *Disabil Rehabil.* 2008;30:1677–1684.
81. Rompe JD, Furia JP, Maffulli N. Mid-portion Achilles tendinopathy—current options for treatment. *Disabil Rehabil.* 2008;30:1666–1676.
82. Vane JR. Introduction: mechanism of action of NSAIDs. *Br J Rheumatol.* 1996;35:1–3.
83. Leadbetter WB. Anti-inflammatory therapy and sports injury: the role of non-steroidal drugs and corticosteroid injection. *Clin Sports Med.* 1995;14:353–410.
84. Almekinders LC. The efficacy of non-steroidal anti-inflammatory drugs in the treatment of ligament injuries. *Sports Med.* 1990;9:137–142.
85. Thorling J, Liden B, Berg R, et al. A double blinded comparison of Naproxen gel and placebo in the treatment of soft tissue injuries. *Curr Med Res Opin.* 1990;12:242–248.
86. Almekinders LC, Temple JD. Etiology, diagnosis, and treatment of tendonitis: an analysis of the literature. *Med Sci Sports Exerc.* 1998;30:1183–1190.
87. Marsolais D, Cote CH, Frenetta J. Nonsteroidal antiinflammatory drug reduces neutrophil and macrophage accumulation but does not improve tendon regeneration. *Lab Invest.* 2003;83:991–999.
88. Weiler JM. Medical modifiers of sports injury. The use of nonsteroidal anti-inflammatory drugs (NSAIDs) in sports soft-tissue injury. *Clin Sports Med.* 1992;11:625–644.
89. Aström M. *On the nature and etiology of chronic achilles tendinopathy.* Thesis. Lund University, Malmö, Sweden: Lund University; 1997.
90. Vogel HG. Mechanical and chemical properties of various connective tissue organs in rats as influenced by non-steroidal antirheumatic drugs. *Connect Tissue Res.* 1977;5:91–95.
91. Forslund C, Bylander B, Aspenberg P. Indomethacin and celecoxib improve tendon healing in rats. *Acta Orthop Scand.* 2003;74:465–469.
92. Virchenko O, Skoglund B, Aspenberg P. Parecoxib impairs early tendon repair but improves later remodeling. *Am J Sports Med.* 2004;32:1–5.
93. Li Z, Yang G, Khan M, et al. Inflammatory response of human tendon fibroblasts to cyclic mechanical stretching. *Am J Sports Med.* 2004;32:435–440.

94. Baud L, Perez J, Denis M, et al. Modulation of fibroblast proliferation by sulfidopeptide leukotrienes: effect of indomethacin. *J Immunol*. 1987;138:1190–1195.
95. Mafi N, Lorentzon R, Alfredson H. Superior short-term results with eccentric calf muscle training compared to concentric training in a randomized prospective multicenter study on patients with chronic Achilles tendinosis. *Knee Surg Sports Traumatol Arthrosc*. 2001;9:42–47.
96. Kannus P, Jozsa L. Histopathological changes preceding spontaneous rupture of a tendon. A controlled study of 891 patients. *J Bone Joint Surg Am*. 1991;73-A:1507–1525.
97. Manias P, Stasinopoulos D. A controlled clinical pilot trial to study the effectiveness of ice as a supplement to the exercise programme for the management of lateral elbow tendinopathy. *Br J Sports Med*. 2006;40:81–85.
98. Alfredson H, Pietila T, Jonsson P, et al. Heavy-load eccentric calf muscle training for treatment of chronic Achilles tendinosis. *Am J Sports Med*. 1998;26:360–366.
99. Roos EM, Engstrom M, Lagerquist A, et al. Clinical improvement after 6 weeks of eccentric exercise in patients with mid-portion Achilles tendinopathy—a randomized trial with 1-year follow-up. *Scand J Med Sci Sports*. 2004;14:286–295.
100. Sayana MK, Maffulli N. Eccentric calf muscle training in non-athletic patients with Achilles tendinopathy. *J Sci Med Sport*. 2007;10:52–58.
101. Rompe JD, Nafe B, Furia JP, et al. Eccentric loading, shock-wave treatment, or a wait-and-see policy for tendinopathy of the main body of tendo Achillis: a randomized controlled trial. *Am J Sports Med*. 2007;35:374–383.
102. Murrell GA. Oxygen free radicals and tendon healing. *J Shoulder Elbow Surg*. 2007;16(5 suppl):S208–S214.
103. Padhiar N, Al-Sayegh H, Chan O, et al. Pennation angle of the soleus in patients with unilateral Achilles tendinopathy. *Disabil Rehabil*. 2008;30:1640–1645.
104. Maffulli N, Longo UG. How do eccentric exercises work in tendinopathy? *Rheumatology (Oxford)*. 2008;47:1444–1445.
105. Maffulli N, Longo UG. Conservative management for tendinopathy: is there enough scientific evidence? *Rheumatology (Oxford)*. 2008;47:390–391.
106. Rompe JD, Furia JP, Maffulli N. Eccentric loading versus eccentric loading plus shock wave treatment for mid-portion Achilles tendinopathy: a randomized controlled trial. *Am J Sports Med*. 2009;37:463–470.
107. Paoloni JA, Appleyard RC, Nelson J, et al. Topical nitric oxide application in the treatment of chronic extensor tendinosis at the elbow: a randomized, double-blinded, placebo-controlled clinical trial. *Am J Sports Med*. 2003;31:915–920.
108. Paoloni JA, Murrell GA. Three-year followup study of topical glyceryl trinitrate treatment of chronic noninsertional Achilles tendinopathy. *Foot Ankle Int*. 2007;28:1064–1068.
109. Paoloni JA, Appleyard RC, Nelson J, et al. Topical glyceryl trinitrate treatment of chronic noninsertional achilles tendinopathy. A randomized, double-blind, placebo-controlled trial. *J Bone Joint Surg Am*. 2004;86-A:916–922.
110. Kane TP, Ismail M, Calder JD. Topical glyceryl trinitrate and noninsertional Achilles tendinopathy: a clinical and cellular investigation. *Am J Sports Med*. 2008;36:1160–1163.
111. Hoksrud A, Ohberg L, Alfredson H, et al. Ultrasound-guided sclerosis of neovessels in painful chronic patellar tendinopathy: a randomized controlled trial. *Am J Sports Med*. 2006;34:1738–1746.
112. Maxwell NJ, Ryan MB, Taunton JE, et al. Sonographically guided intratendinous injection of hyperosmolar dextrose to treat chronic tendinosis of the Achilles tendon: a pilot study. *AJR Am J Roentgenol*. 2007;189:W215–W220.
113. Knobloch K, Schreibermueller L, Longo UG, et al. Eccentric exercises for the management of tendinopathy of the main body of the Achilles tendon with or without an AirHeeltrade mark Brace. A randomized controlled trial. B: Effects of compliance. *Disabil Rehabil*. 2008;30:1692–1696.
114. Knobloch K, Schreibermueller L, Longo UG, et al. Eccentric exercises for the management of tendinopathy of the main body of the Achilles tendon with or without the AirHeeltrade mark Brace. A randomized controlled trial. A: Effects on pain and microcirculation. *Disabil Rehabil*. 2008;30:1685–1691.
115. Knobloch K, Kraemer R, Lichtenberg A, et al. Achilles tendon and paratendon microcirculation in midportion and insertional tendinopathy in athletes. *Am J Sports Med*. 2006;34:92–97.
116. Chan O, O'Dowd D, Padhiar N, et al. High volume image guided injections in chronic Achilles tendinopathy. *Dis Rehabil*. 2008. In press.
117. Rompe JD, Furia J, Weil L, et al. Shock wave therapy for chronic plantar fasciopathy. *Br Med Bull*. 2007;81–82:183–208.
118. Rompe JD, Maffulli N. Repetitive shock wave therapy for lateral elbow tendinopathy (tennis elbow): a systematic and qualitative analysis. *Br Med Bull*. 2007;83:355–378.
119. Giombini A, Giovannini V, Di Cesare A, et al. Hyperthermia induced by microwave diathermy in the management of muscle and tendon injuries. *Br Med Bull*. 2007;83:379–396.
120. Warden SJ. A new direction for ultrasound therapy in sports medicine. *Sports Med*. 2003;33:95–107.
121. D'Vaz AP, Ostor AJ, Speed CA, et al. Pulsed low-intensity ultrasound therapy for chronic lateral epicondylitis: a randomized controlled trial. *Rheumatology (Oxford)*. 2006;45:566–570.
122. Paaavola M, Kannus P, Järvinen TAH, et al. Achilles tendinopathy. *J Bone Joint Surg Am*. 2002;84-A:2062–2076.
123. Maffulli N, Binfield PM, Moore D, et al. Surgical decompression of chronic central core lesions of the Achilles tendon. *Am J Sports Med*. 1999;27:747–752.
124. Maffulli N. Re: Etiologic factors associated with symptomatic Achilles tendinopathy. *Foot Ankle Int*. 2007;28:660; author reply 660–661.
125. Longo UG, Ramamurthy C, Denaro V, et al. Minimally invasive stripping for chronic Achilles tendinopathy. *Dis Rehabil*. 2008. In press.
126. Alfredson H, Ohberg L, Forsgren S. Is vasculo-neural ingrowth the cause of pain in chronic Achilles tendinosis? An investigation using ultrasonography and colour Doppler, immunohistochemistry, and diagnostic injections. *Knee Surg Sports Traumatol Arthrosc*. 2003;11:334–338.
127. Maffulli N, Wong J, Almekinders LC. Types and epidemiology of tendinopathy. *Clin Sports Med*. 2003;22:675–692.
128. Alfredson H, Ohberg L. Neovascularisation in chronic painful patellar tendinosis—promising results after sclerosing neovessels outside the tendon challenge the need for surgery. *Knee Surg Sports Traumatol Arthrosc*. 2005;13:74–80.
129. Yao L, Bestwick CS, Bestwick LA, et al. Phenotypic drift in human tenocyte culture. *Tissue Eng*. 2006;12:1843–1849.
130. Franceschi F, Ruzzini L, Longo UG, et al. Equivalent clinical results of arthroscopic single-row and double-row suture anchor repair for rotator cuff tears: a randomized controlled trial. *Am J Sports Med*. 2007;35:1254–1260.
131. Saxena A, Maffulli N, Nguyen A, et al. Wound complications from surgeries pertaining to the Achilles tendon: an analysis of 219 surgeries. *J Am Podiatr Med Assoc*. 2008;98:95–101.
132. Benazzo F, Stennardo G, Mosconi M, Zanon G, et al. Muscle transplant in the rabbit's Achilles tendon. *Med Sci Sports Exerc*. 2001;33:696–701.
133. Tallon C, Coleman BD, Khan KM, et al. Outcome of surgery for chronic Achilles tendinopathy. A critical review. *Am J Sports Med*. 2001;29:315–320.
134. Mokone GG, Gajjar M, September AV, et al. The guanine-thymine dinucleotide repeat polymorphism within the tenascin-C gene is associated with achilles tendon injuries. *Am J Sports Med*. 2005;33:1016–1021.
135. Mokone GG, Schweltnus MP, Noakes TD, et al. The COL5A1 gene and Achilles tendon pathology. *Scand J Med Sci Sports*. 2006;16:19–26.

136. Jozsa L, Balint JB, Kannus P, et al. Distribution of blood groups in patients with tendon rupture. An analysis of 832 cases. *J Bone Joint Surg Br.* 1989;71:272–274.
137. Kujala UM, Jarvinen M, Natri A, et al. ABO blood groups and musculoskeletal injuries. *Injury.* 1992;23:131–133.
138. Maffulli N, Reaper JA, Waterston SW, et al. ABO blood groups and achilles tendon rupture in the Grampian Region of Scotland. *Clin J Sport Med.* 2000;10:269–271.
139. Caridi G, Pezzolo A, Bertelli R, et al. Mapping of the human COL5A1 gene to chromosome 9q34.3. *Hum Genet.* 1992;90:174–176.
140. Silver FH, Freeman JW, Seehra GP. Collagen self-assembly and the development of tendon mechanical properties. *J Biomech.* 2003;36:1529–1553.
141. Riley G. The pathogenesis of tendinopathy. A molecular perspective. *Rheumatology (Oxford).* 2004;43:131–142.
142. Riley GP. Gene expression and matrix turnover in overused and damaged tendons. *Scand J Med Sci Sports.* 2005;15:241–251.
143. Jones PL, Jones FS. Tenascin-C in development and disease: gene regulation and cell function. *Matrix Biol.* 2000;19:581–596.
144. Rocchi M, Archidiacono N, Romeo G, et al. Assignment of the gene for human tenascin to the region q32-q34 of chromosome 9. *Hum Genet.* 1991;86:621–623.
145. Jarvinen TA, Jozsa L, Kannus P, et al. Mechanical loading regulates the expression of tenascin-C in the myotendinous junction and tendon but does not induce de novo synthesis in the skeletal muscle. *J Cell Sci.* 2003;116:857–866.
146. Jarvinen TA, Jozsa L, Kannus P, et al. Mechanical loading regulates tenascin-C expression in the osteotendinous junction. *J Cell Sci.* 1999;112(Pt 18):3157–3166.
147. Jones FS, Jones PL. The tenascin family of ECM glycoproteins: structure, function, and regulation during embryonic development and tissue remodeling. *Dev Dyn.* 2000;218:235–259.
148. Chiquet M, Renedo AS, Huber F, et al. How do fibroblasts translate mechanical signals into changes in extracellular matrix production? *Matrix Biol.* 2003;22:73–80.
149. Murrell GA. Understanding tendinopathies. *Br J Sports Med.* 2002;36:392–393.
150. Leppilahti J, Puranen J, Orava S. ABO blood group and Achilles tendon rupture. *Ann Chir Gynaecol.* 1996;85:369–371.
151. Smith RK, Birch HL, Goodman S, et al. The influence of ageing and exercise on tendon growth and degeneration—hypotheses for the initiation and prevention of strain-induced tendinopathies. *Comp Biochem Physiol A Mol Integr Physiol.* 2002;133:1039–1050.
152. Movin T, Ryberg A, McBride DJ, et al. Acute rupture of the Achilles tendon. *Foot Ankle Clin.* 2005;10:331–356.
153. Sharma P, Maffulli N. Tendinopathy and tendon injury: the future. *Disabil Rehabil.* 2008;30:1733–1745.