

Efficacy and safety profile of a compound composed of platelet-rich plasma and hyaluronic acid in the treatment for knee osteoarthritis (preliminary results)

Michele Abate¹ · Sandra Verna² · Cosima Schiavone¹ · Patrizia Di Gregorio² · Vincenzo Salini¹

Received: 24 May 2015 / Accepted: 5 August 2015
© Springer-Verlag France 2015

Abstract

Background The combined use of hyaluronic acid and platelet-rich plasma has never been reported in the treatment for osteoarthritis. Aim of this paper was to evaluate the efficacy of this association and to compare retrospectively these results with those of a cohort of patients treated with platelet-rich plasma only.

Materials and methods Subjects with mild-to-moderate knee osteoarthritis were enrolled. After clinical and ultrasound evaluation, patients received a weekly intra-articular injection of 2 ml of hyaluronic acid added with 2 ml of platelet-rich plasma for 3 weeks. Follow-up was performed at 1, 3, and 6 months. The same clinical parameters were retrospectively collected from a cohort of patients treated with 4–5 ml of platelet-rich plasma only.

Results Forty knees were treated in both groups. The intra-group comparison showed a significant improvement in clinical and functional outcomes at 1, 3, and 6 months, while the infra-group comparison did not show any significant difference.

Conclusions The association of platelet-rich plasma + hyaluronic acid has the same efficacy of platelet-rich plasma only, administered in higher volume. We may infer that hyaluronic acid works synergically and improves the activity of several molecules contained in platelet-rich plasma.

Keywords Knee osteoarthritis · Hyaluronic acid · Platelet-rich plasma · Safety profile

Introduction

Knee osteoarthritis (KOA) is a chronic disorder characterized by biochemical and biomechanical alterations of articular cartilage. It is the more common cause of chronic pain and functional impairment, which can compromise overall health and quality of life of the affected patients [1]. Although several conservative treatments (NSAIDs, intra-articular corticosteroids, physical therapies, etc.) have been proposed with varying success rates, none of them has shown to halt, reverse, or modify the normal evolution of the disease [2]. For these reasons in the last decade, there was an increasing interest for therapies able not only to manage clinical symptoms but also to provide an instructional environment for stimulating joint repair [3, 4]. In this framework, platelet-rich plasma (PRP) and hyaluronic acid (HA) injections have been extensively used to manipulate the complex spatio-temporal signaling within and between the joint tissues and to improve lubrication and modulate inflammation, thus restoring a natural healing micro-environment [3]. The clinical studies thus far performed using both compounds separately strongly support their efficacy in the treatment for KOA, in terms of reduced pain and improved function [5, 6]. Moreover, no serious adverse events were observed. In a limited number of studies, patients reported pain, swelling, and mild functional limitation in their joint after injection, which usually disappeared after few days [5, 6].

Recent basic research supports the idea that PRP and HA can favor joint repair through different mechanisms and therefore can be advantageously associated without

✉ Michele Abate
m.abate@unich.it

¹ Department of Medicine and Science of Aging, University G. d'Annunzio, Chieti-Pescara, Via dei Vestini 31, 66013 Chieti Scalo, CH, Italy

² Immunohaematology and Transfusional Medicine Service, "SS. Annunziata" Hospital, Chieti Scalo, CH, Italy

altering the original relevant characteristics of both products [3]. Excellent results have been preliminarily reported in the treatment for Morton neuroma, pressure ulcers, and surgical wounds [7–9]. However, the association of these two therapeutic agents has never been investigated in patients suffering from KOA. At this regard, it has been recently introduced in the market a new compound which provides, in a single-step closed system, an immediate formation of a cell-friendly HA network in which platelets are dispersed.

Aim of this paper was twofold: first, to report preliminary results about the efficacy and safety profile of the compound composed of both these two therapeutic agents in patients suffering from KOA, and second, to compare retrospectively these results with those obtained from a group of patients treated with PRP only.

Materials and methods

Patients suffering for more than 3 months from mild-to-moderate KOA (grade II–III according to Kellgren–Lawrence score on radiographic examination performed at least 3 months before) were enrolled. Exclusion criteria were the following: age >80 years, recent knee trauma, intra-articular injection with steroids, HA and/or PRP, current systemic treatments with steroids or NSAIDs within the previous 3 months, rheumatic pathologies (rheumatoid, psoriatic and reactive arthritis, arthritis associated with inflammatory bowel diseases, and spondyloarthritis), severe systemic diseases (renal, hepatic, cardiac, infections, endocrinopathies, malignancies), immunodepression, anti-coagulant or antiaggregant therapies, Hb values <11 g/dl, and/or platelet values <150.000/mm³.

At baseline, demographic and anthropometric data were collected. In each subject, height and weight were measured, and BMI was then calculated. Clinical and functional measures included pain during the previous week both at rest and during activities (visual analogue scale [VAS]), Knee Injury and Osteoarthritis Outcome Score [KOOS], and weekly NSAID consumption (number of patients and tablets/weeks). Moreover, an ultrasound (US) evaluation of the knee joint was carried out according to the standard protocol to investigate the presence of joint effusion and/or synovitis [10].

Afterward, the association between PRP and HA was prepared after harvesting of 4 ml of autologous blood into a pre-filled tube containing 2 ml of HA [natural, non-cross-linked fermented HA (1550 kDa), concentration: 20 mg/ml (40 mg total)] in addition to the thixotropic cell separation gel. After centrifugation (single spin, 3500 rpm for 5 min), it provided 2 ml of PRP (1,6–1,8x, no leukocytes) combined with 2 ml of HA (total volume = 4 ml).

Then, in sterile conditions, patients received a weekly intra-articular injection (lateral approach) of the compound PRP + HA for 3 weeks. When present, articular effusion was withdrawn. After each injection, the patients were kept under observation for approximately 30 min (monitoring early side effects) and then discharged from the Unit. At home, patients were asked to restrict the use of the leg for at least 24 h; rest, ice packs, and acetaminophen (NSAIDs were forbidden) were allowed. Moreover, patients were asked to register possible adverse events (pain, swelling, heat, functional limitations) and acetaminophen consumption during the following days after the injection. During the treatment period, mild activities (pool or bike exercise) were permitted, and subsequently, a gradual return to sport or recreational activities was allowed.

Functional and US evaluation was repeated after 1, 3, and 6 months, and patients' satisfaction was registered by means of five-point Likert Scale (not at all satisfied; slightly satisfied; somewhat satisfied; very satisfied; extremely satisfied) [11].

In order to compare the results obtained in the PRP + HA group, the same clinical and functional parameters were retrospectively collected from a cohort of patients suffering from KOA, who had been treated beforehand with PRP only and evaluated with the same standard protocol in this Unit. This PRP preparation (4–5 ml, 3x, no leukocytes) had been obtained after centrifugation (single spin, 3500 rpm for 5 min) of 8 ml of whole blood. Patients had received three PRP injections (once a week) and had been instructed to follow the same post-treatment regimen described for the PRP + HA group.

The procedure followed was in accordance with the Declaration of Helsinki, and informed written consent was obtained from each patient.

Data are reported as mean \pm SD for continuous measures, and as frequencies and percentage for dichotomous and categorical variables. The two-sample Student's *t* test was used to compare continuous variables, when the distribution of data was normal; the Wilcoxon's rank sum test was used otherwise. The χ^2 test was used to evaluate associations between categorical data. The significance level was determined at $p < 0.05$.

Results

Forty patients suffering from mild-to-moderate KOA were enrolled in both groups. At baseline, no significant demographic and clinical differences were observed among groups (Table 1). In the participants treated with PRP + HA (Table 2) and with PRP only (Table 3), VAS scores, both at rest and during activities, decreased

Table 1 Demographic and clinical data of enrolled patients at baseline

	PRP + HA	PRP	<i>p</i> value
Age (years)	56.7 ± 11.2	60.9 ± 9	0.1
M/F ratio	31:9	21:19	
BMI	23.7 ± 2	24.1 ± 1.6	0.3
Symptoms duration (months)	11.4 ± 5.3	10.1 ± 4.6	0.2
Knee side (R:L)	22:18	27:13	
K-L II:III	23:17	19:21	
VAS at rest	2.9 ± 2.2	3.1 ± 2.4	0.5
VAS during activities	6.3 ± 2	6.3 ± 2.6	0.9
KOOS	60.7 ± 14.7	53.5 ± 16.3	0.3
NSAIDs (no. of patients)	15	13	
Tablets/weeks	1.6 ± 0.6	1.7 ± 0.6	0.7

significantly, and accordingly, knee function (KOOS) improved throughout the whole length of the study.

Weekly NSAID consumption at 6 months was significantly reduced. In the PRP + HA group, the patients receiving NSAIDs were 37.5 % (15/40) at baseline and only 12.5 % (5/40) at 6 months, with a weekly tablet consumption which passed from 1.6 ± 0.6 to 1.4 ± 0.5. In the PRP-only group, the figures were 32.5 % (13/40) versus 10 % (4/40), and 1.7 ± 0.6 versus 1 ± 0, at baseline and after 6 months, respectively. The articular effusion/synovial inflammation evaluated by means of US was also reduced (baseline: 8 and 6 knees in the PRP + HA and PRP only, respectively; 6 months: 4 and 3 knees in the PRP + HA and PRP only, respectively). At the end of the study, 82 % (PRP + HA) and 77 % (PRP only) of patients were extremely/very satisfied from the treatment.

The infra-group comparison (PRP + HA vs PRP only) did not show any significant difference between groups in all the clinical evaluations during the different follow-up periods (Figs. 1, 2, 3). In both groups, mild adverse events after injection (pain, heat, redness) were observed in a very

limited number of patients (2 and 3 in the PRP + HA and PRP-only group, respectively). These effects lasted less than 24–48 h and did not require the use of any medication.

Discussion

This study shows that the association of PRP + HA is effective and safe in the treatment for patients suffering from mild-to-moderate KOA. Indeed, at 6 months, the VAS pain score, both at rest and during activities, substantially decreased, whereas knee function (KOOS) was clearly improved. The use of NSAIDs (number of patients and tablets/week) and joint inflammation were also reduced, while side effects were mild and present in a very low number of participants.

Similar findings have been observed also in the cohort of patients retrospectively enrolled, with comparable clinical and demographic characteristics, and treated beforehand in this Unit with 4–5 of PRP only.

These positive clinical results can be related to the ability of both PRP and HA to regulate various healing mechanisms into the joint [3]. Several experimental researches have clearly demonstrated that the release of signaling proteins (including growth factors and chemokines) present into PRP can positively influence tissue regeneration [3, 12, 13]. Indeed, these molecules can modulate the inflammatory response, induce cell migration and proliferation, and regulate angiogenesis and cell differentiation, thus interfering with the catabolic microenvironment in OA joints. Moreover, it has been observed that PRP is able to stimulate migration and differentiation of human subchondral cells into chondrocytes highlighting the consequences of manipulating the biological milieu [3, 12, 13].

The ability to improve joint homeostasis has been also demonstrated for HA. Beside its role in

Table 2 Clinical data during follow-up in PRP + HA patients

	VAS rest	<i>p</i>	VAS activities	<i>p</i>	KOOS	<i>p</i>
Baseline	2.9 ± 2.2		6.3 ± 2		60.7 ± 14.7	
1 month	2 ± 2.1	0.008	4.6 ± 2.4	0.000	61.8 ± 18.5	0.68
3 months	1.7 ± 2	0.001	4.2 ± 2.1	0.000	66.7 ± 16.4	0.01
6 months	1.3 ± 1.1	0.000	3.6 ± 1.5	0.000	67 ± 12.7	0.009

Table 3 Clinical data during the follow-up in PRP patients

	VAS rest	<i>p</i>	VAS activities	<i>p</i>	KOOS	<i>p</i>
Baseline	3.1 ± 2.4		6.3 ± 2.6		53.5 ± 16.3	
1 month	1.9 ± 2.1	0.001	4.6 ± 2.3	0.000	59.6 ± 13.3	0.007
3 months	1.9 ± 1.5	0.001	4.1 ± 2.2	0.000	61.3 ± 12.3	0.001
6 months	1.6 ± 1.9	0.000	3.8 ± 2.4	0.000	65.5 ± 14.6	0.000

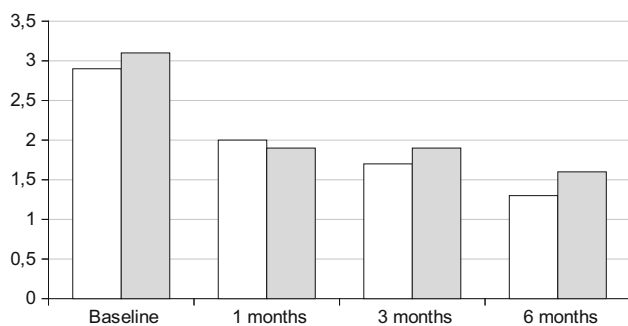


Fig. 1 Comparison between groups: VAS at rest and follow-up (white PRP + HA; gray PRP)

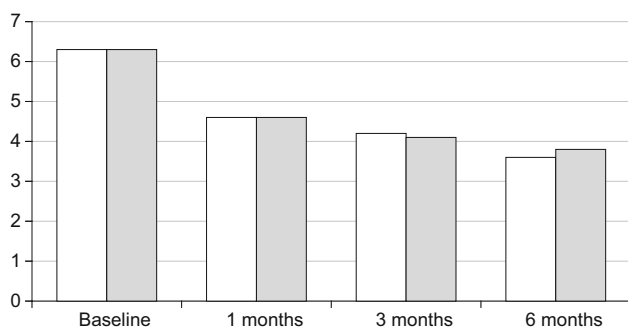


Fig. 2 Comparison between groups: VAS during activities and follow-up (white PRP + HA; gray PRP)

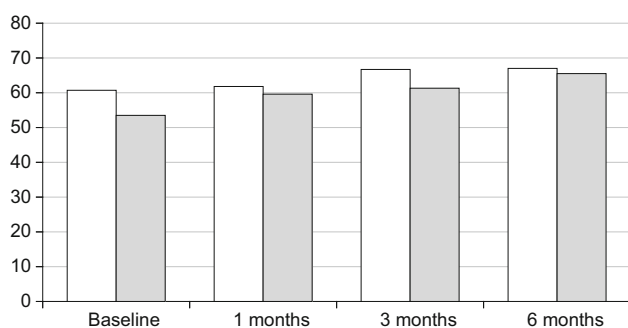


Fig. 3 Comparison between groups: KOOS and follow-up (white PRP + HA; gray PRP)

viscosupplementation (HA substitution), basic research, performed in different OA animal models, has shown that HA is provided with several pleiotropic signaling properties (immunosuppressive, anti-inflammatory, anti-apoptotic, anti-angiogenic, anti-fibrotic and analgesic effects, with normalization of endogenous HA synthesis) [14].

These observations are in agreement with several clinical trials where PRP or HA used separately showed a very large treatment effects for knee pain and function compared to pre-injection values [5, 6]. In the few studies where the two agents were compared, PRP showed better

results than HA in patients with mild-to-moderate KOA at 6- to 12-month follow-up [15–17].

This experimental protocol adds information about the utility of the association of PRP + HA. In particular, the equivalence of positive results obtained in the two study groups deserves some considerations. Actually, it must be underlined that the PRP volume used for PRP-only group was almost twofold compared to the PRP + HA group (4–5 vs. 2 ml). On the basis of this observation, we may infer that the mechanisms exerted by PRP and HA might be additive when both products are injected together without altering their original relevant characteristics. As a matter of fact, the compound here proposed provides, in a single-step closed system, an immediate formation of a cell-friendly HA network in which platelets are dispersed. It is conceivable that HA increases the residence time of the growth factors and facilitates their release to reach the target by creating a pericellular bioactive scaffold around the cells. The molecular diffusion and the proteins' presentation to their receptors located in the cytoplasmic membrane of the target competent cell could be therefore facilitated.

So, the signaling molecules released from PRP could change easier the secretory pattern of synovial cells, responsible of more favorable biological conditions within the joint.

Recent experimental studies support these assumptions. For example, in co-culture models (synovial cells and chondrocytes), it has been observed that TNF- α production was decreased using both PRP and HA, while IL-6 and metalloproteinases were decreased only in HA and PRP cultures, respectively, suggesting that these agents influence inflammation through different mechanisms [18]. Further basic research, aiming to evaluate the PRP potential to induce tendon cells and synovial fibroblasts migration and to examine whether the combination of PRP with HA improves their motility in vitro, showed that PRP stimulated the migration of fibroblasts, as well as HA, but this effect was more prominent when HA was combined with PRP (+335 %) [19]. In another experimental study, cartilage defects filled with scaffolds made of HA and PRP showed better histological results at 6 months, compared with HA alone, being filled by a repair tissue with some features of hyaline cartilage [20]. In addition, the idea of positive interactions between HA and PRP is also supported by an elegant experiment in mice where HA, stabilizing some growth factors (i.e., bone morphogenetic protein 2), enhanced the reparative processes [21]. These experiments taken together suggest that the association of HA and PRP can influence and facilitate the cells division, migration, and differentiation; this is relevant since mesenchymal stem cells have been identified in the synovium and in the synovial fluid.

Currently, no clinical studies in the treatment for OA support these basic experiments. However, excellent results of the PRP + HA association have been reported in the healing of pressure ulcers and surgical wounds, and in Morton neuroma surgery [7–9], but these anecdotal findings need confirmation by controlled trials.

Apart from the clinical results, this study demonstrated that the association of PRP + HA is safe. Indeed, mild and very short-lasting side effect (pain, heat, redness) have been observed and positively treated in a very limited number of patients. Their onset could be ascribed to the presence of the pro-inflammatory molecules in the PRP and/or to the characteristics of HA itself [13]. This is particularly true in knees where an effusion and/or synovitis was already detectable, as observed at the US examination in these patients.

The present study suffers some limitations. It is a retrospective observational trial including a limited number of patients with a short follow-up period (6 months). A placebo effect, which usually ranges 15–30 %, cannot be ruled out. In addition, arthrocentesis can be considered as a form of symptomatic treatment *per se* as the altered inflammatory synovial fluid is removed. Moreover, because several patients may get better with non-pharmacological treatments (patient education, weight loss, exercise), this bias should be avoided. More importantly, given that it is unknown what of the two components plays a major role, future studies should be performed to compare three patients groups, treated with HA, PRP, and the association, respectively. This could allow to state whether the added autologous plasma with platelets enhances the therapeutic activity of HA used alone. Assuming that we target synovial cells and mesenchymal stem cells from the synovial niche, the ability to understand and control the factors that play a role in the therapeutic effect of this association shall guide the optimization and design of the combination [i.e., optimal ratio, molecular weight of HA (low or high molecular weight), optimal PRP formulation, volumes]. In conclusion, the association of PRP and HA is effective and safe in the management of patients suffering from mild-to-moderate KOA. However, these findings need confirmation by controlled trials with a larger number of patients and longer follow-up period.

Compliance with ethical standards

Conflict of interest The authors disclose any conflicts of interest related to the research or the manuscript or to any previous presentation of the research, manuscript, or abstract. They assure that authorship has been granted only to those individuals who have contributed substantially to the research or manuscript.

Informed consent The procedure followed was in accordance with the Declaration of Helsinki, and informed written consent was obtained from each patient.

References

- Alshami AM (2014) Knee osteoarthritis related pain: a narrative review of diagnosis and treatment. *Int J Health Sci (Qassim)* 8(1):85–104
- Jevsevar DS (2013) Treatment of osteoarthritis of the knee: evidence-based guideline, 2nd edition. *J Am Acad Orthop Surg* 21(9):571–576
- Andia I, Abate M (2014) Knee osteoarthritis: hyaluronic acid, platelet-rich plasma or both in association? *Expert Opin Biol Ther* 14(5):635–649
- Musumeci G, Castrogiovanni P, Leonardi R, Trovato FM, Szychlinska MA, DiGiunta A, Loreto C, Castorina S (2014) New perspectives for articular cartilage repair treatment through tissue engineering: a contemporary review. *World J Orthop* 5(2):80–88
- Petrella R (2005) Hyaluronic Acid for the treatment of knee osteoarthritis: long-term outcomes from a naturalistic primary care experience. *Am J Phys Med Rehabil* 84(4):278–283
- Rodriguez-Merchan EC (2013) Intraarticular injections of platelet-rich plasma (PRP) in the management of knee osteoarthritis. *Arch Bone Jt Surg* 1(1):5–8
- Cervelli V, Lucarini L, Spallone D, Palla L, Colicchia GM, Gentile P, De Angelis B (2011) Use of platelet-rich plasma and hyaluronic acid in the loss of substance with bone exposure. *Adv Skin Wound Care* 24(4):176–181
- De Angelis B, Lucarini L, Orlandi F, Agovino A, Migner A, Cervelli V, Izzo V, Curcio C (2013) Regenerative surgery of the complications with Morton's neuroma surgery: use of platelet rich plasma and hyaluronic acid. *Int Wound J* 10(4):372–376
- Ramos-Torrecillas J, García-Martínez O, De Luna-Bertos E, Ocaña-Peinado FM, Ruiz C (2015) Effectiveness of platelet-rich plasma and hyaluronic acid for the treatment and care of pressure ulcers. *Biol Res Nurs* 17(2):152–158
- Vlad V, Iagnocco A (2012) Ultrasound of the knee in rheumatology. *Med Ultrason* 14(4):318–325
- Kolarz G, Kotz R, Hochmayer I (2003) Long-term benefits and repeated treatment cycles of intra-articular sodium hyaluronate (Hyalgan) in patients with osteoarthritis of the knee. *Semin Arthritis Rheum* 32(5):310–319
- Andia I, Maffulli N (2013) Platelet-rich plasma for managing pain and inflammation in osteoarthritis. *Nat Rev Rheumatol* 9(12):721–730
- Andia I, Abate M (2013) Platelet-rich plasma: underlying biology and clinical correlates. *Regen Med* 8(5):645–658
- Abate M, Pulcini D, Di Iorio A, Schiavone C (2010) Viscosupplementation with intra-articular hyaluronic acid for treatment of osteoarthritis in the elderly. *Curr Pharm Des* 16(6):631–640
- Guler O, Mutlu S, Isyar M, Seker A, Kayaalp ME, Mahirogullari M (2015) Comparison of short-term results of intraarticular platelet-rich plasma (PRP) and hyaluronic acid treatments in early-stage gonarthrosis patients. *Eur J Orthop Surg Traumatol* 25(3):509–513
- Say F, Gürler D, Yener K, Bülbül M, Malkoc M (2013) Platelet-rich plasma injection is more effective than hyaluronic acid in the treatment of knee osteoarthritis. *Acta Chir Orthop Traumatol Cech* 80(4):278–283
- Spaková T, Rosocha J, Lacko M, Harvanová D, Gharaibeh A (2012) Treatment of knee joint osteoarthritis with autologous platelet-rich plasma in comparison with hyaluronic acid. *Am J Phys Med Rehabil* 91(5):411–417
- Sundman EA, Cole BJ, Karas V, Della Valle C, Tetreault MW, Mohammed HO, Fortier LA (2014) The anti-inflammatory and matrix restorative mechanisms of platelet-rich plasma in osteoarthritis. *Am J Sports Med* 42(1):35–41

19. Anitua E, Sanchez M, De la Fuente M, Zalduendo MM, Orive G (2012) Plasma rich in growth factors (PRGF-Endoret) stimulates tendon and synovial fibroblasts migration and improves the biological properties of hyaluronic acid. *Knee Surg Sports Traumatol Arthrosc* 20(9):1657–1665
20. Marmotti A, Bruzzone M, Bonasia DE, Castoldi F, Rossi R, Piras L, Maiello A, Realmuto C, Peretti GM (2012) One-step osteochondral repair with cartilage fragments in a composite scaffold. *Knee Surg Sports Traumatol Arthrosc* 20(12):2590–2601
21. Srinivasan PP, McCoy SY, Jha AK, Yang W, Jia X, Farach-Carson MC, Kirn-Safran CB (2012) Injectable perlecan domain 1-hyaluronan microgels potentiate the cartilage repair effect of BMP2 in a murine model of early osteoarthritis. *Biomed Mater* 7(2):024109