



A study to compare the efficacy of corticosteroid therapy with platelet-rich plasma therapy in recalcitrant plantar fasciitis: A preliminary report

Vijay D. Shetty M.S. (Orthopaedics)^{a,*}, Mandeep Dhillon M.S. (Orthopaedics)^b,
Chintan Hegde M.S. (Orthopaedics)^a, Prajyot Jagtap M.S. (Orthopaedics)^a,
Suvini Shetty M.D. (Pathology)^c

^a Hiranandani Orthopaedic Medical Education (HOME), Dr L. H. Hiranandani Hospital, Hillside Avenue, Hiranandani Gardens, Powai, Mumbai 400076, India

^b Department of Orthopaedics, Post Graduate Institute of Medical Education and Research (PGIMER), Chandigarh 160012, India

^c Department of Pathology, Dr L. H. Hiranandani Hospital, Hillside Avenue, Hiranandani Gardens, Powai, Mumbai 400076, India

ARTICLE INFO

Article history:

Received 10 June 2013

Received in revised form 4 August 2013

Accepted 8 August 2013

Keywords:

Plantar fasciitis

Corticosteroid injection

Platelet rich plasma injection

ABSTRACT

Background: Plantar fasciitis is one of the commonest, and most frustrating, foot ailments seen in a regular orthopaedic clinic. There are a number of modalities available to treat this condition, of which corticosteroid injection is, perhaps, the most popular. However, recent years have seen an increased interest in the use of platelet-rich plasma (PRP) injections in various clinical situations such as plantar fasciitis.

Methods: We undertook a prospective non-randomized study to compare the efficacy of traditional corticosteroid injection (Steroid group) to PRP injection (PRP group), in a cohort of patients.

Results: We studied both groups of patients before and after the injections using Visual Analogue Score (VAS), the Foot & Ankle Disability Index (FADI) and American Foot and Ankle Score (AFAS). Our study confirms that there is significant clinical improvement in PRP group at three months after the injection.

Conclusion: The use of PRP injection can be an attractive alternative in the treatment of disabling, recalcitrant plantar fasciitis.

Study design: Cohort study.

Level of clinical evidence: Level 3.

© 2013 European Foot and Ankle Society. Published by Elsevier Ltd. All rights reserved.

1. Introduction

Plantar fasciitis (PF), both acute and chronic, is one of the commonest foot ailments [1]. More than two million individuals are treated for chronic PF on an annual basis, in the United States alone, accounting for 11 to 15% of visits related to foot ailments [2].

PF is considered a self-limiting condition. However, it may require a resolution time ranging from 6 to 18 months and sometimes even longer which can lead to frustration on both, the physician and the patient [3,4]. There are many treatment modalities available for PF, both medical and surgical, with variable success rates.

The primary treatment for PF is rest and avoidance of aggravating activity; this provides significant pain relief. According to Wolgin et al. [5], rest was the treatment that worked best for 25% of PF patients whereas a pair of proper shoes or change of footwear

was considered by 14% of PF patients as the treatment that worked best [6]. Strapping, taping or accommodative heel cups and orthotics may be effective components of a PF treatment plan [7]. Other treatment options include stretching and strengthening exercises, night splinting and walking cast [5,8,9].

Traditionally, if conservative treatment for chronic plantar fasciitis failed, corticosteroids were administered which provided temporary pain relief [9,10]. However, recurrences after steroid injections are well known. This has led to the use of other, safe, injection forms such as PRP. The logic is that PRP enhances local healing thereby improved clinical outcome [11]. This is a preliminary report of a study to compare the efficacy of corticosteroid injection to PRP injection in PF. To our knowledge, this is the first study comparing the efficacy of two forms of injections in the treatment of difficult clinical scenario of PF.

2. Patients and methods

This study was commenced after obtaining approval from the Institutional Ethics Committee. Plantar fasciitis (PF) was defined as

* Corresponding author. Tel.: +91 2225763203; fax: +91 2225763311.
E-mail address: vijayshetty@gmail.com (V.D. Shetty).

pain over the medial part of the foot at the origin of plantar fascia and over its course; with pain on direct palpation and on forced dorsiflexion. All individuals with *recalcitrant* PF visiting our institution from July 2010 were evaluated. Patients were divided into two groups; those receiving corticosteroid (steroid group) and those receiving PRP (PRP group). It was pre-decided to include 60 patients with 30 patients in either group.

Patients with PF of minimum 3 months duration with previous unsuccessful conservative therapy were considered eligible for the study. Individuals with previous surgery for PF, diagnosis of vascular insufficiency or neuropathy related to heel pain and previous exposure to corticosteroid therapy were excluded from the study. All the eligible participants were explained about both procedures in detail including pros and cons. This was followed by their informed consent. By August 2011, we could include 60 patients who met the inclusion criteria and agreed to participate in the study.

The patients were assessed, before and after the injection, using Visual Analogue Score (VAS) [12], the Foot & Ankle Disability Index

(FADI) [13] and American Foot and Ankle Score (AFAS) [14]. The intervention was later on administered in the form of injections of either PRP or Steroid according to the group. The patients were again evaluated during the follow up visits three months after the injections.

2.1. Corticosteroid injection procedure

Under aseptic precautions, a mixture of 40 mg of triamcinolone acetonide (Kenacort, Nicholas Piramal, India) and 3 ml of 2% lignocaine (Xylocaine, Aestus Enterprises, India) was injected into the tender spot and then dressed with an occlusive dressing. The patient was then mobilised.

2.2. Platelet-rich plasma injection procedure

Under aseptic precautions venipuncture was performed, at the antecubital vein, using an IV cannula which was then secured to skin. 54 ml of blood was drawn into a syringe containing 6 ml of

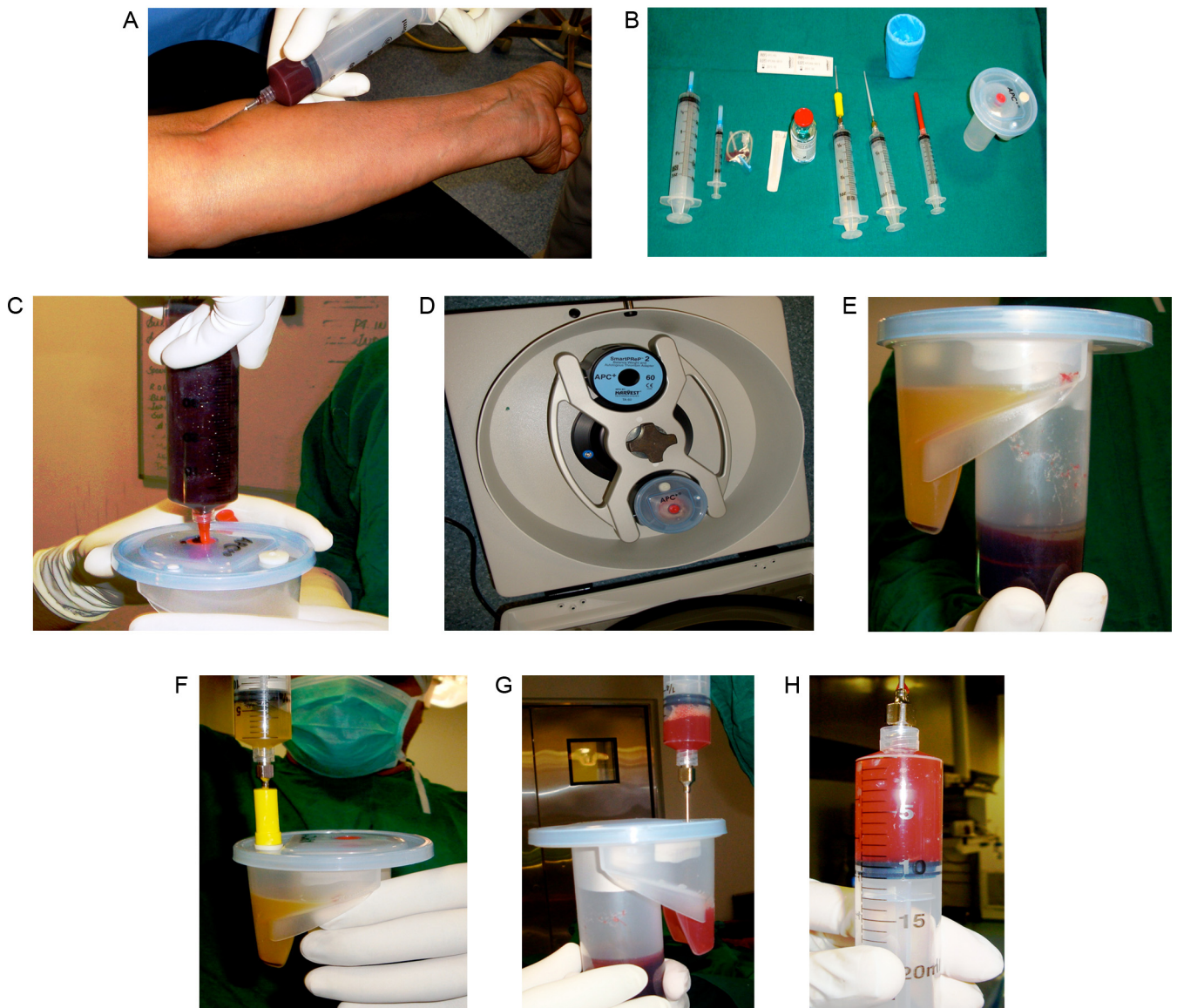


Fig. 1. (A) Drawing blood from the patient. (B) Platelet rich plasma kit. (C) Transferring blood into processing disposable (PD) via red access site. (D) PD placed into centrifuge system with appropriate balance weight. (E) PD after centrifuge showing PRP with supernatant PPP. (F) Removing PPP via yellow access site using a syringe with spacer. (G) Re-suspension of remaining PRP. (H) PRP ready for injection. (For interpretation of the references to color in the artwork, the reader is referred to the web version of the article.)

anticoagulant Anticoagulant Citrate Dextrose Solution - Formula A (ACD-A) and adequately mixed (Fig. 1A). Its contents (60 ml) were dispensed into the blood chamber of the processing disposable (PD) of the SmartPREP system (Harvest Technologies Corporation, Plymouth, MA, USA; Fig. 1B) through the red access site via a blunt needle cannula (Fig. 1C). The plasma chamber of the PD was loaded with two millilitres of ACD-A. The PD was then placed into the SmartPREP centrifuge with the appropriate reusable balance weight (BW) in the opposite bucket (Fig. 1D). The centrifuge kit was spun for 14 min (Fig. 1E). Using the plasma syringe with the blunt cannula, the supernatant platelet-poor plasma (PPP) was withdrawn from plasma chamber until air entered the syringe and then discarded (Fig. 1F). The remaining platelet concentrate in the plasma chamber was then resuspended by withdrawing the fluid and gently injecting it back into the plasma chamber (Fig. 1G). This step was repeated two to three times until 10 ml of uniform, concentrated platelet-rich plasma (PRP) was formed (Fig. 1H). The PRP sample was then transferred to the sterile red specimen cup, of which two millilitres was sent to the laboratory for analysis of platelet concentration. The remainder was drawn into a sterile syringe using an 18 gauge needle. Under aseptic precautions, and local anaesthesia, the PRP sample was injected into the most tender spot of the affected foot, which was then dressed with an occlusive dressing and the patient was mobilised. The total time from drawing blood to injection was about 30 min.

2.3. Statistical analysis

The statistical analysis was carried out using SPSS 16.0 and MS Excel 2003. Statistical analyses tested the null hypotheses of no differences in patients treated with either group at 95% significance level. Chi square test, paired and unpaired t test were carried out.

3. Results

The age and sex distribution of the subjects of this study are shown in Table 1. As shown in Table 2 there is highly significant difference in both groups for all post-operative outcome measures (VAS, AFAS and FADI), with much better improvement in the PRP group as compared to the Steroid group (Fig. 2A and B).

Table 1

Age and sex distribution of the groups.

Characteristics	PRP (30)	Steroid (30)
Age (mean)	34.0 (SD – 9.15)	39.2 (SD – 9.35)
Sex		
Male	11 (36.7)	13 (43.3)
Female	19 (63.3)	17 (56.7)

4. Discussion

Plantar fasciitis (PF) is a common clinical problem with many available treatment modalities. Traditional treatment for PF includes rest, analgesics and stretching exercises. Injections, particularly corticosteroids, are given in very acute situations and for cases unresponsive to conservative methods. Corticosteroids offer a quick fix for pain relief in the acute phase but have limited effect in chronic cases with a significant fraction of patients suffering from relapse and recurrence [6,8,15–17]. In chronic cases, surgery is the last resort with very unpredictable results. Recent years have seen an increase in the use of PRP in various clinical situations, though there is no clear and hard evidence in the literature to support the use of PRP for PF in clinical practice.

This study was designed to compare the efficacy of corticosteroid therapy to PRP therapy for PF. PRP contains a more concentrated amount of platelets than does whole blood. Within platelets are powerful growth factors, including platelet-derived growth factor, transforming growth factor beta, and epidermal growth factor. The injection of PRP into the affected tissue initiates the healing stages necessary to reverse the degenerative process at the base of the plantar fascia. The individual cytokines present in the platelet α -granules have been shown to enhance fibroblast migration and proliferation, up-regulate vascularisation and increase collagen deposition in a variety of in vitro and in vivo settings [18]. Additionally, many of these cytokines have been seen to work in a dose dependent manner. The concentrated growth factors work in a synergetic manner to initiate a tendon healing response. Transforming growth factor β 1 is shown to significantly increase type I collagen production by tendon sheath fibroblasts. This same mechanism is likely to be active in chronic plantar fasciitis [19].

Table 2

Pre-operative and post-operative parameters in both groups.

Group	PRP			Steroid			p Value
	Mean	Std. deviation	Std. error of mean	Mean	Std. deviation	Std. error of mean	
Pre-op VAS	8.1	1.322	0.241	7.8	1.126	0.206	0.348
Post-op VAS	1.8	1.126	0.206	4.27	1.413	0.258	0.000
Pre-op AFAS	33.9	8.155	1.489	32.5	7.157	1.307	0.483
Post-op AFAS	83.1	10.111	1.846	70.5	9.187	1.677	0.000
Pre-op FADI	32.03	5.91	1.079	35.23	6.585	1.202	0.052
Post-op FADI	90.47	7.445	1.359	63.3	8.972	1.638	0.000

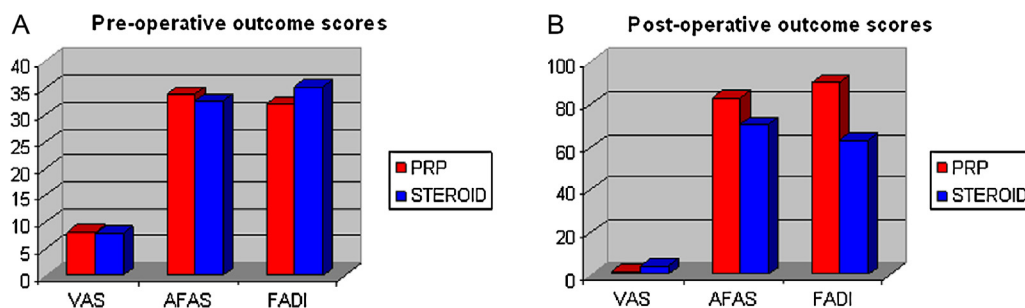


Fig. 2. (A) Pre-operative outcome scores. (B) Post-operative outcome scores.

In 2010, Peerbooms et al. [20] studied 100 patients and demonstrated a positive effect of PRP for tennis elbow. This report describes the first comparison of an autologous platelet concentrate with corticosteroid injection as a treatment for tennis elbow in patients who have had unsuccessful non-operative treatment. It demonstrates that a single injection of concentrated autologous platelets improves pain and function more than corticosteroid injection. These improvements were sustained over time with no reported complications. Barrett and Erredge [21] reported a 78% success rate with PRP in PF patients in 1-year follow-up. The same authors also documented a decrease in plantar fascia thickness, detected by ultrasound, over time when treated with PRP.

This was not a pure non-randomised trial. Blinding of both participants and treatment providers was also not possible in the study. Although this study involves a small number of patients with a short follow up period, we believe that the study has a potential to change our clinical practice in relation to PF therapy.

5. Conclusion

We believe that PRP injection is safe and can be an excellent alternative to corticosteroid injection in plantar fasciitis, not responsive to conservative means. The findings of this preliminary study can be very relevant in clinical practice. However, these findings should be taken in context to the limitations of the study.

Conflict of interest statement

All the authors declare that there are no conflicts of interest regarding this article and no source of funding has been received.

References

- [1] Riddle DL, Schappert SM. Volume of ambulatory care visits and patterns of care for patients diagnosed with plantar fasciitis: a national study of medical doctors. *Foot Ankle Int* 2004;25(5):303–10. PMID- 15134610.
- [2] Gibbon WW, Long G. Ultrasound of the plantar aponeurosis (fascia). *Skeletal Radiol* 1999;28:21–6. PMID- 10068071.
- [3] Young CC, Rutherford DS, Niedfeldt MW. Treatment of plantar fasciitis. *Am Fam Physician* 2001;63(3): 467–74, 477–8. PMID- 11272297.
- [4] Rompe JD. Plantar fasciopathy. *Sports Med Arthrosc* 2009;17(2):100–4. PMID- 19440137.
- [5] Wolgin M, Cook C, Graham C, et al. Conservative treatment of plantar heel pain: longterm follow-up. *Foot Ankle Int* 1994;15: 97–10. PMID- 7951946.
- [6] Tatli Y, Kapasi S. The real risks of steroid injections for plantar fasciitis, with a review of conservative therapies. *Curr Rev Musculoskelet Med* 2009;2(1):3–9. PMID- 19468912.
- [7] Seligman DA, Dawson DR. Customized heel pads and soft orthotics to treat heel pain and plantar fasciitis. *Arch Phys Med Rehabil* 2003;84:1564–7. PMID- 14586928.
- [8] Acevedo JJ, Beskin JL. Complications of plantar fascia rupture associated with corticosteroid injection. *Foot Ankle Int* 1998;19(2):91–7.
- [9] Gudeman SD, Eisele SA, Heidt Jr RS, et al. Treatment of plantar fasciitis by iontophoresis of 0.4% dexamethasone. A randomised, double-blind, placebo-controlled study. *Am J Sports Med* 1997;25(3):312–6.
- [10] Crawford F, Atkins D, Young P, et al. Steroid injection for heel pain: evidence of short-term effectiveness. A randomised controlled trial. *Rheumatology (Oxford England)* 1999;38(10):974–7.
- [11] Steven P, Arnoczky, Delos D, Rodeo SA. What is platelet-rich plasma? *Oper Techn Sport Med* 2011;19(3):142–8.
- [12] Huskisson EC. Measurement of pain. *J Rheumatol* 1982;9(5):768–9.
- [13] Martin RL, Burdett RG, Irrgang JJ. Development of the foot and ankle disability index (FADI). *J Orthop Sports Phys Ther* 1999;29:A32–3.
- [14] Kitaoka HB, Alexander IJ, Adelaar RS, et al. Clinical rating systems for the ankle-hindfoot, midfoot, hallux, and lesser toes. *Foot Ankle Int* 1994;15(7):349–53.
- [15] Lemont H, Ammirati M, Usen N. Plantar Fasciitis – a degenerative process (fasciosis) without inflammation. *J Am Podiatr Med Assoc* 2003;93(3):234–7.
- [16] Wearing SC, Smeathers JE, Urry SR, et al. The pathomechanics of plantar fasciitis. *Sports Med* 2006;36(7):585–611.
- [17] Kim C, Cashdollar MR, Mendicino RW, et al. Incidence of plantar fascia ruptures following corticosteroid injection. *Foot Ankle Spec* 2010;3(6):335–7 [Epub].
- [18] Molloy T, Wang Y, Murrell G. The roles of growth factors in tendon and ligament healing. *Sports Med* 2003;33:381–94.
- [19] Wrotniak M, Bielecki T, Gazdzik T. Current opinion about using the platelet-rich gel in orthopaedics and trauma surgery. *Orthop Traumatol Rehabil* 2007;9:227–38.
- [20] Peerbooms J, et al. Positive effect of an autologous platelet concentrate in lateral epicondylitis in a double blind randomised controlled trial: PRP versus corticosteroid injection with a 1 year follow-up. *Am J Sports Med* 2010;38: 255–62.
- [21] Barrett S, Erredge S. Growth factors for chronic plantar fasciitis. *Podiatr Today* 2004;17:37–42.