

# Platelet-rich Plasma as an Effective Treatment for Proximal Hamstring Injuries

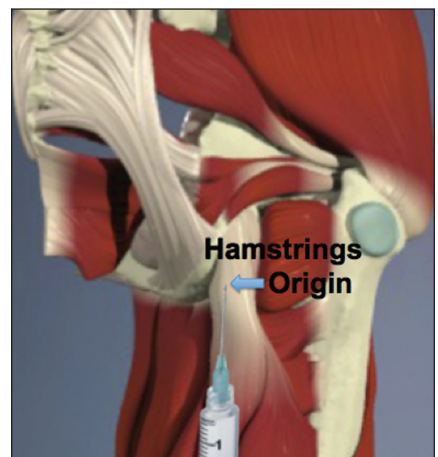
ROBERT J. WETZEL, MD; RONAK M. PATEL, MD; MICHAEL A. TERRY, MD

## abstract

Full article available online at [Healio.com/Orthopedics](https://www.healio.com/Orthopedics). Search: 20121217-20

Proximal hamstring injuries can be disabling, and several traditional conservative treatments, including physiotherapy and nonsteroidal anti-inflammatory drugs, have been inconsistent. Corticosteroid injections have demonstrated success but can adversely affect local tissues. Platelet-rich plasma (PRP) has emerged as a safe, effective treatment for several orthopedic pathologies. The authors propose a PRP injection at the muscle origin as a novel treatment for proximal hamstring injuries.

A retrospective review yielded 15 patients with 17 proximal hamstring injuries. Twelve injuries failed traditional conservative treatment and were ultimately treated with a PRP injection at the hamstrings muscle origin. Five patients were treated with traditional conservative treatment alone. Analysis included pre- and posttreatment visual analog scale scores, Nirschl Phase Rating Scale scores, and return to sport. No significant difference existed between the groups' pretreatment visual analog scale scores ( $P=.28$ ) and Nirschl Phase Rating Scale scores ( $P=.15$ ) and their posttreatment visual analog scale scores ( $P=.38$ ) and Nirschl Phase Rating Scale scores ( $P=.22$ ). The PRP group demonstrated a reduction in visual analog scale scores ( $P<.01$ ) and Nirschl Phase Rating Scale scores ( $P<.01$ ), but the traditional conservative treatment group did not demonstrate the same reduction ( $P=.06$  and  $.06$ , respectively). All athletes returned to their desired activity level with no major complications.



**Figure:** Anatomic illustration of the location of the injection into the hamstrings muscle origin at the ischial tuberosity.

*The authors are from the Department of Orthopaedic Surgery, Northwestern University Feinberg School of Medicine, Chicago, Illinois.*

*Drs Wetzel and Patel have no relevant financial relationships to disclose. Dr Terry is a consultant for Smith & Nephew; received grant funding from Smith & Nephew and DePuy; and received compensation for expert testimony, honoraria, and royalties from Smith & Nephew. Funding for the study's statistician was received from a fellowship and research support grant from Smith & Nephew.*

*The authors acknowledge Stephen Gryzlo, MD, Sara Edwards, MD, and Rajat Verma, BS, for their contributions to this study.*

*Correspondence should be addressed to: Robert J. Wetzel, MD, Department of Orthopaedic Surgery, Northwestern University Feinberg School of Medicine, 676 N Saint Clair, Ste 1350, Chicago, IL 60611 (robertjwetzel@gmail.com).*

*doi: 10.3928/01477447-20121217-20*

Proximal hamstring injuries can be disabling and persistent.<sup>1</sup> They are common in many sports and have been described as prevalent in most endurance sports (eg, marathons, triathlons, and long-distance running), soccer, Australian rules football, rugby, sprinting, track and field, water skiing, and hockey.<sup>2-4</sup> These injuries often occur acutely due to a forcibly flexed hip with an extended knee. Chronic injuries are more common in runners, particularly sprinters, and patients with repeated injuries.<sup>3</sup> A broad spectrum of treatment modalities, including rest, activity modification, specific exercises, medications, injections, and surgery, have had a varying range of efficacy.<sup>5,6</sup>

Traditional conservative treatment methods include physiotherapy, activity modification, home exercise programs, rest, compression wraps, and ice massage.<sup>3</sup> Medical interventions, such as nonsteroidal anti-inflammatory drugs (NSAIDs), have been reported to acutely limit, but not eradicate, tissue inflammation; NSAIDs have also been reported to inhibit tissue healing when used long term and are only recommended for a duration of 3 to 7 days.<sup>7</sup> Procedural treatments, such as corticosteroid injections, have been reported to speed return to play in professional football players but have also shown major side effects, such as slowed long-term tissue healing due to inhibition of collagen linkage, incomplete healing, and repeat injuries.<sup>7-9</sup> Minor side effects of corticosteroid injections are atrophy of subcutaneous fat and skin hypopigmentation. Open surgical repair using periosteal suture and anchors in chronic injuries has shown good to excellent results, even in refractory cases that have failed conservative measures.<sup>4,10</sup> However, surgical intervention for proximal hamstring injuries carries the risk of complications, including infection, nerve damage (posterior femoral cutaneous nerve and sciatic), deep vein thrombosis, and other wound-related complications.<sup>4,6</sup> In addition, open surgical repair would likely necessitate a prolonged rehabilitation program and increased absence from sport.

Thus, optimizing nonoperative therapy has remained the mainstay of proximal hamstring tendinopathies. Efforts to avoid surgery and enhance nonoperative management have led to new and innovative treatment modalities. A recent randomized, controlled trial showed superior results with shockwave therapy compared with traditional conservative treatment in chronic proximal hamstring tendinopathies in professional athletes.<sup>3</sup> Platelet-rich plasma (PRP) injections are another treatment option in sports medicine. Platelet-rich plasma has been reported to be an effective treatment for muscle and tendon injury in general and hamstring injuries specifically.<sup>11</sup> Platelet-rich plasma is a concentrated sample of autologous blood, which contains a higher-than-serum concentration of platelets and a variety of growth factors, such as platelet-derived growth factor, vascular endothelial growth factor, transforming-growth factor- $\beta$ 1, fibroblast growth factor, epidermal growth factor, hepatocyte growth factor, and insulin-like growth factor-1. These cytokines have been demonstrated to have regenerative properties at various stages of the inflammatory cascade.<sup>12</sup>

Because it is an autologous substance, side effects are minimal and limited to complications with the initial blood draw, including hematoma, venous thrombosis at the phlebotomy site, and infection. Similarly, mild complications of the same nature, such as infection, minor bleeding, and injury to structures with the injection needle, are a possibility during injection of PRP into the affected body site. Although large-scale Level I randomized, controlled trials on the use of PRP are lacking, several smaller case series and retrospective reviews have been guiding the broad application of PRP.<sup>12</sup> Nonoperative and operative applications have been described, including Achilles tendon repair, anterior cruciate ligament reconstruction, subacromial decompression, muscle injury, rotator cuff repair, and elbow epicondylitis.<sup>10-15</sup>

The current authors injected PRP into the hamstring origin at the ischial tuber-

osity in a small series of patients who remained symptomatic after completing traditional nonoperative treatments. To the authors' knowledge, the results of PRP application in proximal hamstring tendinopathies have not been reported outside of 1 international case report from Qatar.<sup>11</sup> The current authors' initial traditional conservative treatment management strategy consisted of 6 to 12 weeks of physical therapy and 1 week of NSAIDs followed by as-needed use. Patients who failed to respond to these measures were candidates for PRP injections. This article presents the clinical results of 15 patients with 17 proximal hamstring tendinopathies who were managed under the authors' treatment algorithm by 3 surgeons (M.A.T.) at 1 institution. The hypothesis was that PRP would provide adequate pain relief, reliable return to sport, and increased functional outcomes for proximal hamstring injuries that did not improve despite traditional conservative treatment.

## MATERIALS AND METHODS

After institutional review board approval, the records of patients diagnosed and treated for proximal hamstring injuries at the authors' institution between 2008 and 2011 were identified using ICD-9 and Current Procedural Terminology codes as filters. Inclusion criteria were a clinical diagnosis of tendinopathy, strain, or partial tears confirmed by a sports medicine fellowship-trained orthopedic surgeon (M.A.T.) and a radiologic diagnosis with magnetic resonance imaging (MRI). Patients with complete proximal hamstring tears or ischial tuberosity avulsion fractures were excluded. After a thorough review of all patient matches, it was determined that 17 diagnoses in 15 patients fulfilled the inclusion criteria. The medical records and imaging studies of these patients were reviewed.

Ten patients (12 hamstrings) had either a persistent, unacceptable pain level or incomplete return to preinjury function after 6 to 12 weeks of physical therapy and 1

week of scheduled NSAIDs use and were deemed to have failed traditional conservative treatment. They formed the cohort that received the PRP injection. The primary indication for PRP injection was persistence of clinical symptoms, including pain, weakness, and an inability to return to baseline activity after traditional conservative treatment had been completed and failed. The 5 remaining patients responded well to conservative measures and were able to return to preinjury activity with acceptable pain levels. The medical records were reviewed pre- and posttreatment for physical examination, pain, and functional assessments. Pre- and posttreatment visual analog scale (VAS) scores, return to work status, return to preinjury sport status, and overall satisfaction with the procedure were recorded. Nirschl Phase Rating Scale (NPRS) scores were also collected, which, to the authors' knowledge, is the only hamstring-specific scoring system reported in the literature.<sup>3,13</sup> The foundation of this rating scale was originally described by Blazina et al<sup>14</sup> in 1973 and was then modified and applied by Nirschl and Ashman<sup>13</sup> in 2003 to rate patients' pain with elbow tendinopathies. Cacchio et al<sup>3</sup> used this scale to describe results of patients after shockwave therapy to chronic proximal hamstring tendinopathies. The NPRS has 7 phases of disability based on injury severity (Table 1).<sup>3,13</sup>

Follow-up data and demographics were collected using a retrospective chart review and by telephone interview conducted by one of the authors (R.J.W., R.M.P.). All patients were instructed to return for a follow-up visit if questions or concerns were discovered during the telephone interview. These outcome measures were gathered in the summer of 2011 and did not specifically correlate with particular follow-up dates for outpatients.

The PRP group comprised 8 women and 2 men, and the traditional conservative treatment (TCT) group comprised 4 women and 1 man. In the PRP group, 9 of the 10 patients were collegiate or high-level (eg, marathon runner or triathlete) athletes. In

Table 1

Nirschl Phase Rating Scale	
Phase	Level of Disability
1	Mild stiffness or soreness after activity with resolution of symptoms within 24 hours.
2	Mild stiffness or soreness prior to activity that is relieved by warm-up; symptoms are not present during activity but return afterward and resolve within 48 hours.
3	Pain that is present during activity without causing activity modification.
4	Pain with activity that causes modification.
5	Pain that is present during all activities and occurs with activities of daily living.
6	Intermittent rest pain that does not disturb sleep.
7	Constant rest pain that disturbs sleep.

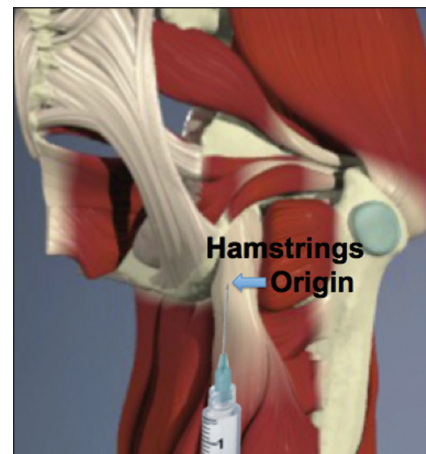
*Adapted from Cacchio et al<sup>3</sup> and Nirschl and Ashman.<sup>13</sup>*

the TCT group, no patients were collegiate athletes, and 2 patients were high-level athletes. Neither group contained professional athletes. The patients in the PRP group presented an average of 9.6 months after injury and received 6 to 12 weeks of physical therapy prior to PRP treatment. Nine patients in this group also used scheduled NSAIDs during the first week of physical therapy, followed by as-needed use; NSAIDs were medically contraindicated in 1 patient. All patients in this group had unacceptable relief of symptoms on completion of traditional conservative treatment.

Patients in the TCT group presented an average of 7.8 months after injury and received 6 to 12 weeks of physical therapy. Four of the 5 patients used scheduled NSAIDs during the first week of physical therapy, followed by as-needed use. No patient in either group received a corticosteroid injection in the proximal hamstring area or had been given oral systemic steroids for treatment of their tendinopathy, although 1 patient in the PRP group was taking chronic steroids for adrenal insufficiency.

**Injection Technique and Postinjection Protocols**

All patients in the PRP group received a single-volume, 6-cc PRP injection from a 55-cc blood draw in the office or operating room by the senior author (M.A.T.). The



**Figure:** Anatomic illustration of the location of the injection into the hamstrings muscle origin at the ischial tuberosity.

injection was administered using the GPS-III system (Biomet, Warsaw, Indiana). The patient was positioned in a lateral decubitus or prone position. The planned injection site was sterilized with a 2% chlorhexidine gluconate solution, and a spinal needle was inserted through the skin. The needle was directed toward the ischial tuberosity using direct palpation (Figure). The needle was then withdrawn a few millimeters, and the PRP was administered into the muscle origin. One patient received a second injection into the same site 6.5 months after the initial injection due to only partial resolution of her symptoms.

Table 2

**PRP Group Pre- and Posttreatment VAS and NPRS Scores**

Patient Age, y	VAS		NPRS	
	Pre	Post	Pre	Post
44	8	5	4	3
44	5	1	3	1
53	9	3	5	2
43	8	0	7	1
49	10	2	7	4
48	9	1	5	1
60	7	0	4	1
19	8	0	5	1
19	10	0	7	2
19	8	0	5	1
17	8	0	7	1
17	8	0	7	1
Mean	8.2	0.7	5.5	1.5

Abbreviations: NPRS, Nirschl Phase Rating Scale; Post, posttreatment; Pre, pretreatment; PRP, platelet-rich plasma; VAS, visual analog scale.

All patients were protected from excessive activity of the injured limb, especially hip flexion beyond 30°, by using crutches or a rolling crutch device for a minimum of 3 weeks posttreatment. After 3 weeks, patients returned for follow-up and safely transitioned off of their precautions. Either formal physical therapy or a home exercise regimen taught by a physical therapist was initiated for the next 6 weeks. Return to formal physical therapy was largely a factor of the patients' insurance and not based on the authors' recommendations. Five of the 10 patients were placed in a hip abduction brace during the initial 3 weeks as an additional protective measure when compliance with hip flexion precautions was a concern. Brace use was largely driven by patients' personal concerns and was not a strict requirement instituted by the attending surgeon. If symptoms resolved after 6 weeks of home therapy following re-

Table 3

**TCT Group Pre- and Posttreatment VAS and NPRS Scores**

Patient Age, y	VAS		NPRS	
	Pre	Post	Pre	Post
31	7	1	5	2
32	5	2	4	3
40	7	1	5	2
47	8	0	4	1
64	10	2	4	2
Mean	7.4	1.2	4.4	2

Abbreviations: NPRS, Nirschl Phase Rating Scale; Post, posttreatment; Pre, pretreatment; TCT, traditional conservative treatment; VAS, visual analog scale.

moval of precautions, formal office follow-up was encouraged but not mandatory. The sequence of events for a patient in the PRP group was (1) presentation with a hamstrings injury, (2) completion of 6 to 12 weeks of formal physical therapy with 1 week of NSAIDs use, (3) persistence of symptoms, (4) traditional conservative treatment deemed to have failed, (5) PRP injection administered, (6) patient protected for 3 weeks with hip precautions, (7) additional physical therapy or home regimen for 6 weeks after removal of precautions, and (8) follow-up based on symptom resolution.

**Follow-up**

Patients in the PRP group followed up an average of 4.5 months after treatment. The TCT group followed up an average of 2 months after initiation of their treatment plan.

**Statistical Analysis**

Results were analyzed by a professional statistician using various nonparametric versions of the *t* test to determine whether the pre- and posttreatment scores had achieved a statistically significant difference. As in a Student's *t* test, a *P* value less

than .05 indicated statistical significance in the nonparametric versions. Data analysis was conducted by the Northwestern University Feinberg School of Medicine Biostatistics Collaboration Center.

**RESULTS**

Average patient age of the entire study cohort was 38 years (range, 17-64 years). Average age was 37.1 years in the PRP group and 42.8 years in the TCT group (*P* = .64). Average time from symptom onset to clinical presentation was 289 days (9.6 months; range, 74-1146 days) in the PRP group and 234 days (7.8 months, range, 47-577 days) in the TCT group (*P* = .64). Average follow-up was 4.5 months (range, 1-24 months) in the PRP group and 2 months (range, 1-6 months) in the TCT group (*P* = .91). Age, presentation, and follow-up data were analyzed using the Mann-Whitney *U* test (nonparametric analog to independent-samples *t* test). All other data were analyzed using a Wilcoxon signed rank sum test (nonparametric version of the paired-samples *t* test).

**Visual Analog Scale Scores**

Average pre- and posttreatment VAS scores were 8.2 and 0.7 (*P* < .01), respectively (Table 2). In the TCT group, initial average VAS was 7.4, and reduced to 1.2 after treatment (*P* = .06) (Table 3), demonstrating no statistically significant reduction in VAS in this group. No significant differences existed between initial (*P* = .28) and posttreatment (*P* = .38) VAS scores between the groups.

**Nirschl Phase Rating Scale Scores**

The PRP group had an initial mean NPRS score of 5.5, which was reduced to 1.5 after treatment (*P* < .01). Similarly, mean pre- and posttreatment NPRS scores in the TCT group were 4.4 and 2 (*P* = .06), respectively. Comparative analysis of NPRS scores between the groups at presentation demonstrated no difference (*P* = .15), nor did analysis of NPRS scores after treatment (*P* = .22) (Table 4).



**Return to Sport**

Two (40%) of the 5 patients in the TCT group were high-level but not professional or collegiate athletes, and they returned to their desired level of participation. In the PRP group, 8 of the 10 patients were competitive or collegiate athletes and 1 patient was a high-level but not a professional or collegiate athlete. The 1 nonathletic patient in this group had a complicated medical history, including extensive posterior spinal fusion, adrenal insufficiency, and chronic oral steroid use. The 9 athletes all returned to their desired activity level or previously competitive level of sport.

No complications occurred from the PRP injections. One patient required a second injection 6.5 months after the first due to only partial symptom improvement. This patient subsequently achieved baseline activity and function level after the second injection. In addition, no patient failed to return to full work activities due to their injury or treatment. No specific complaints arose about the PRP injection itself other than the slight, brief pain from the injection and the blood draw, which was expected.

**DISCUSSION**

This study demonstrates that proximal hamstring injuries can be treated with a PRP injection into the muscle origin when traditional conservative treatment fails. Some cases can be treated conservatively and achieve successful results with physical therapy and NSAIDs alone. Other cases do not respond as well to traditional conservative treatment, and the literature suggests either a corticosteroid injection or operative repair as the next possible step in management.<sup>4,8</sup> The current results support that PRP would be a logical nonoperative addition to the armamentarium of treatment modalities for proximal hamstrings tendinopathies, specifically those that have failed traditional conservative treatment. All patients in this study who received PRP experienced symptom resolution and returned to sport an average of 4.5 months posttreatment. In addition, patients in the

PRP group were the only patients to demonstrate statistically significant reductions in VAS pain scores and NPRS functional outcomes measurements.

**Historical Treatments**

Corticosteroid injection use has been historically controversial. Despite this, corticosteroid injection use has been reported in the literature to treat the pain and inflammation associated with proximal hamstring injuries, but results have been variable.<sup>7</sup> Concern for further tendon degeneration and rupture with steroid injections has prompted some practitioners to abandon corticosteroid injection and seek other treatment methods.<sup>4,15</sup> Operative interventions, including debridement, tenotomy of the semimembranosus tendon distal to the origin, and reapproximation of the proximal aspect of the biceps femoris, were described by Lempainen et al.<sup>4</sup> In their cohort of 47 patients (48 cases; 1 bilateral), 42 (88%) cases had an excellent or good result and 6 (13%) had a fair or poor outcome. Forty-two (88%) cases returned to preinjury level of sport at an average of 5 months (range, 1-12 months). Two patients required additional surgery, 1 reported a superficial wound infection, 1 experienced hypertrophic scarring, and 1 experienced hyperaesthesia due to a likely injury to the posterior femoral cutaneous nerve.

**Platelet-rich Plasma Applications in the Literature**

Platelet-rich plasma has been an area of increased research in orthopedics and many other surgical subspecialties.<sup>16,17</sup> Although the safety of PRP is well established, its efficacy has not yet been confirmed.<sup>18</sup> Nevertheless, its use in promoting tissue healing has increased, especially given the lack of reported complications or harmful effects.<sup>19</sup> In 2012, several continued applications of PRP have been described. Plastic reconstructive surgeons have described its angiogenic potential and ability to increase survivorship in cutaneous flaps in animal models.<sup>20</sup> Dermatologists have

Table 4

Comparative Student's <i>t</i> Test Analysis			
TCT Group	PRP Group	<i>P</i> <sup>a</sup>	
Pre-VAS	Pre-VAS	.28	
Post-VAS	Post-VAS	.38	
Pre-VAS	Post-VAS	.06	
	Pre-VAS	Post-VAS	<.01
Pre-NPRS	Pre-NPRS	.15	
Post-NPRS	Post-NPRS	.22	
Pre-NPRS	Post-NPRS	<.01	
	Pre-NPRS	Post-NPRS	.06

*Abbreviations: NPRS, Nirschl Phase Rating Scale; PRP, platelet-rich plasma; TCT, traditional conservative treatment; VAS, visual analog scale.*  
<sup>a</sup>Less than .05 was considered a statistically significant difference.

advocated its use due to its ability to promote hair growth.<sup>21</sup> In orthopedic surgery, PRP has been widely described for adjunctive tendon or ligament healing in rotator cuff repair or anterior cruciate ligament reconstruction, as well as numerous other applications, such as elbow epicondylitis, patellar tendonitis, Achilles tendon ruptures, subacromial decompressions, plantar fasciitis, and knee osteoarthritis.<sup>12,16,22-25</sup> Although PRP has been extensively studied in rotator cuff tendinopathy and tendon tears, no conclusive evidence in its favor has been accepted. However, it is accepted that PRP may stimulate a healing response and could be useful in accelerating an athlete's recovery from injury. This study demonstrates another specific use of PRP, but further research must be conducted for generalized applicability.

**Study Limitations**

The inherent biases and limitations of a retrospective case series, such as selection bias, limited this study. In addition, the

follow-up examination and VAS scores were recorded during last clinical follow-up. The NPRS scores were collected from chart review and retrospectively completed as needed during follow-up telephone interviews, which subjects the data to recall bias. Moreover, the study lacked a true control group of patients who continued nonoperative treatment or underwent another procedure, such as corticosteroid injection, for a more direct comparison. Finally, the number of patients was limited, decreasing the power of the study. However, the size of the cohort is understandable given the incidence of the disease. In hindsight, more thorough data collection could have been conducted, and VAS and NPRS data from the PRP group could have been compared before and after traditional conservative treatment and then again before and after injection. This may have resulted in a more specific analysis of the direct effects of PRP on the patients' symptoms.


The authors do not feel that the study was biased based on time to presentation or posttreatment follow-up because these time points were not statistically significant. If a study of this nature were to be organized in the future, it would have a prospective design, a dedicated control group, and a standardized physical therapy regimen in every patient. Also, if a large enough patient population could be evaluated, a subgroup analysis based on age, specific sport, and collegiate or professional athlete status vs noncompetitive athlete status would be imperative to generalize the results to different populations.

## CONCLUSION

This study shows that all patients who received PRP had a significant reduction in pain and disability when comparing VAS and NPRS scores, even after failing traditional conservative treatment. All patients were able to return to preinjury baseline level of activity and sport, including 9 (100%) of 9 athletes. Results in the TCT group demonstrated no significant reduc-

tion in VAS and NPRS scores. No difference existed between pre- and posttreatment scores between the groups. This suggests that PRP may be a superior treatment for proximal hamstring injuries.

Traditional conservative treatment demonstrated no significant decrease in pain and functional scores; however, based on the small series, this is only applicable in approximately 29% (5 of 17 hamstrings) of cases. It is important to note that 12 (71%) of 17 hamstrings failed traditional conservative treatment and were deemed refractory cases. After receiving PRP as the next treatment option, these patients were able to produce post-treatment VAS and NPRS scores superior to those in the TCT group. The results in the PRP group and the small percentage (29%) of patients who responded well to traditional conservative treatment suggest that it may be beneficial to use PRP as a primary agent in conjunction with traditional conservative treatment for the initial treatment of proximal hamstring injuries. This may be especially true in high-level athletes and those looking to avoid corticosteroid injection or surgery.

Based on the data, the authors cannot conclusively determine that PRP is a superior treatment; however, the data suggest that PRP is superior, and this hypothesis could be the basis for future research into the new field of orthobiologics. The authors acknowledge the need for a larger-scale, randomized, prospective comparison study to more accurately demonstrate the true effects of PRP. This study adds to the growing number of favorable reports suggesting the efficacy of PRP as a successful treatment for tendinopathies. 

## REFERENCES

1. Chakravarthy J, Ramisetty N, Pimpalnerkar A, Mohtadi N. Surgical repair of complete proximal hamstring tendon ruptures in water skiers and bull riders: a report of four cases and review of the literature. *Br J Sports Med.* 2005; 39(8):569-572.
2. Carlson C. The natural history and management of hamstring injuries. *Curr Rev Musculoskelet Med.* 2008; 1(2):120-123.

3. Cacchio A, Rompe JD, Furia JP, Susi P, Santilli V, De Paulis F. Shockwave therapy for the treatment of chronic proximal hamstring tendinopathy in professional athletes. *Am J Sports Med.* 2011; 39(1):146-153.
4. Lempainen L, Sarimo J, Heikkila J, Mattila K, Orava S. Surgical treatment of partial tears of the proximal origin of the hamstring muscles. *Br J Sports Med.* 2006; 40(8):688-691.
5. Orchard J, Best TM. The management of muscle strain injuries: an early return versus the risk of recurrence. *Clin J Sports Med.* 2002; 12(1):3-5.
6. Harris JD, Griesser MJ, Best TM, Ellis TJ. Treatment of proximal hamstring ruptures: a systematic review. *Int J Sports Med.* 2011; 32(7):490-495.
7. Drezner JA. Practical management: hamstring muscle injuries. *Clin J Sports Med.* 2003; 13(1):48-52.
8. Levine WN, Bergfeld JA, Tessendorf W, Moorman CT. Intramuscular corticosteroid injection for hamstring injuries: a 13-year experience in the national football league. *Am J Sports Med.* 2000; 28(3):297-300.
9. Kennedy JC, Willis RB. The effects of local steroid injections on tendons: a biomechanical and microscopic correlative study. *Am J Sports Med.* 1976; 4(1):11-21.
10. Young JJ, van Riet RP, Bell SN. Surgical release for proximal hamstring syndrome. *Am J Sports Med.* 2008; 36(12):2372-2378.
11. Hamilton B, Knez W, Eirale C, Chalabi H. Platelet enriched plasma for acute muscle injury. *Acta Orthop Belg.* 2010; 76(4):443-448.
12. Hall MP, Band PA, Meislin RJ, Jazrawi LM, Cardone DA. Platelet-rich plasma: current concepts and application in sports medicine. *J Am Acad Orthop Surg.* 2009; 17(10):602-608.
13. Nirschl RP, Ashman ES. Elbow tendinopathy: tennis elbow. *Clin Sports Med.* 2003; 22(4):813-836.
14. Blazina H, Kerlan R, Jobe F. Jumper's knee. *Orthop Clin North Am.* 1973; 4(3):665-678.
15. Paavola M, Kannus P, Järvinen TA, Järvinen TL, Józsa L, Järvinen M. Treatment of tendon disorders. Is there a role for corticosteroid injection? *Foot Ankle Clin.* 2002; 7(3):501-513.
16. Sanchez M, Anitua E, Azofra J, Andia I, Padilla S, Mujika I. Comparison of surgically repaired Achilles tendon tears using platelet-rich fibrin matrices. *Am J Sports Med.* 2007; 35(2):245-251.
17. Fleming BC, Spindler KP, Palmer MP, Magarian EM, Murray MM. Collagen-platelet composites improve the biomechanical properties of healing anterior cruciate ligament grafts in a porcine model. *Am J Sports Med.* 2009; 37(8):1554-1563.

18. Bava ED, Barber FA. Platelet-rich plasma products in sports medicine. *Phys Sportsmed*. 2011; 39(3):94-99.
19. Jo CH, Kim JE, Yoon KS, et al. Does platelet-rich plasma accelerate recovery after rotator cuff repair? A prospective cohort study. *Am J Sports Med*. 2011; 39(10):2082-2090.
20. Li W, Enomoto M, Ukegawa M, et al. Subcutaneous injections of platelet-rich plasma into skin flaps modulate proangiogenic gene expression and improve survival rates. *Plast Reconstr Surg*. 2012; 129(4):858-866.
21. Li ZJ, Choi HI, Choi DK, et al. Autologous platelet-rich plasma: a potential therapeutic tool for promoting hair growth. *Dermatol Surg*. 2012; 38(7 pt 1):1040-1046.
22. Sanchez M, Azofra J, Anitua E, et al. Plasma rich in growth factors to treat an articular cartilage avulsion: a case report. *Med Sci Sports Exerc*. 2003; 35(10):1648-1652.
23. Silva A, Sampaio R. Anatomic ACL reconstruction: does the platelet-rich plasma accelerate tendon healing? *Knee Surg Sports Traumatol Arthrosc*. 2009; 17(6):676-682.
24. Mishra A, Woodall J, Vieira A. Treatment of tendon and muscle using platelet-rich plasma. *Clin J Sports Med*. 2009; 28(1):11-125.
25. Arnoczky SP, Caballero O, Yeni YN. On the horizon from the ORS. *J Am Acad Orthop Surg*. 2010; 18(7):445-448.